The New England
Journal of Medicine

Copyright, 1949, by the Massachusetts Medical Society

Volume 241 DECEMBER 22, 1949 Number 25

GENERALIZED INTESTINAL POLYPOSIS AND MELANIN SPOTS OF THE ORAL MUCOSA, LIPS AND DIGITS*

A Syndrome of Diagnostic Significance

HAROLD JEGHERS, M.D.,† VICTOR A. McKUSICK, M.D.,‡ AND KERMIT H. KATZ, M.D.§

WASHINGTON, D. C., BALTIMORE, MARYLAND, AND BOSTON, MASSACHUSETTS

IN 1944, a brief report was made by one of us[1] regarding the association, in 2 patients, of a distinctive type of melanin pigmentation of the oral mucosa, lips and digits with intestinal polyposis.

Since then 10 cases, including the 2 referred to above, have been collected from five different hospitals and are reported here in detail along with a review of pertinent literature and a discussion of the significance of this syndrome.

CASE REPORTS

CASE 1. A 14-year-old American schoolgirl entered the Fifth Medical Service of the Boston City Hospital on March 11, 1939, with the complaint of persistent diarrhea of 6 weeks' duration. There were five or six watery bowel movements each day. No mucus, blood or fat was ever noted in the stools. Intermittently during this period there were bouts of vomiting. Her appetite was good. There was no pain, but the patient noted frequent loud gurgling noises in the abdomen. During the present illness there was a 4-pound weight loss.

Twice in 1933 she had been operated upon at another hospital for intussusception and intestinal obstruction. On the second occasion a portion of the ileum was resected. Polyps of the stomach, ileum and sigmoid were found at that time. So far as could be ascertained the family history was noncontributory. The parents believed the spots on the lips had been present since early childhood and apparently had not changed over the years.

Physical examination revealed a thin, rather undernourished patient appearing acutely ill. The hair and irides were dark brown. The skin was pale. On the face, concentrated about the mouth, and on the lips and oral mucous membrane were numerous small, brown-black spots. Similar areas of pigmentation were noted on the dorsal surface of the fingers (Fig. 1). A few pigmented spots were also observed on the toes. There were two small patches of vitiligo on the back. The heart and lungs were normal. The abdomen was moderately distended, with tenderness over the upper half. Loud borborygmi were present. The liver edge was palpable two fingerbreadths below the right costal margin. There was slight clubbing of the fingers and toes. Examination otherwise was negative.

The blood pressure was 85/40.

Examination of the blood showed a red-cell count of 2,410,000, with a hemoglobin of 70 per cent, and a white-cell count of 7400, with a normal differential count. The red cells were slightly hyperchromic and macrocytic. The blood Hinton test was negative. The urine was normal. The stools were loose, brown and guaiac negative. Gastric analysis revealed 24 units of free hydrochloric acid and 46 units of total acid. Barium-enema study by the double contrast method showed multiple negative shadows consistent with polyps scattered throughout the large intestine. Many small clusters of two to four polyps in the sigmoid and rectum were directly visualized on sigmoidoscopic examination. No areas of pigmentation were noted.

A regimen of symptomatic measures supplemented by frequent administration of liver extract and iron resulted in disappearance of the diarrhea, with improvement in weight and a subjective feeling of well-being, and with an increase in the hemoglobin to 88 per cent and in red-cell count to 3,300,000. The patient was discharged after 6 weeks in the hospital.

On August 19, she was readmitted to the hospital because of a return of diarrhea during the preceding month. The findings were as on the previous entry, and satisfactory improvement resulted from similar therapy. She was discharged in 3 weeks.

Lobar pneumonia due to a Type I pneumococcus necessitated readmission on November 21. There was no bacteremia. Treated with sulfapyridine and general supportive measures, she failed to show any response and died on December 1.

At autopsy pigmentation of the skin as previously described was noted.

Death was due to lobar pneumonia of the right lung. The pleural cavity was normal, as were the heart and pericardial cavity.

The esophagus was normal. The mucosa of the stomach bore three soft pedunculated polyps ranging from 1.5 to 2.5 cm. in diameter, one lying just below the cardiac orifice, a second on the greater curvature, and a third near the pyloric sphincter of the stomach. The mucosa otherwise was normal, as was the duodenum. The jejunum and ileum showed some brownish-black, granular pigment along the edge of the mucosal folds. In addition, a polyp occurred every 50 to 60 cm. These averaged 1 to 2 cm. in diameter and were attached to pedicles that were 0.5 to 1.0 cm. in length. The terminal ileum contained the largest polyp in the gastrointestinal tract; this measured 4.5 cm. in diameter. One mulberry-like polyp measuring 1.5 cm. was present in the sigmoid portion of the large intestine.

The liver weighed 1960 gm. It was of normal color and consistence and on section bore the usual geographic markings. Microscopical examination showed lipoid vacuolization of the liver cells at the central portions of the lobules.

*From the Fifth and Sixth (Boston University) Medical Services, Boston City Hospital, and the Department of Medicine, Boston University School of Medicine; the Medical Clinic and School of Medicine, Johns Hopkins University and Hospital; and the Department of Medicine, Georgetown University School of Medicine.

†Director and professor, Department of Medicine, Georgetown University School of Medicine; physician-in-chief, Georgetown University Hospital; consulting physician, Boston City Hospital.

‡Assistant in medicine, Johns Hopkins University School of Medicine.

§Assistant director, Fifth and Sixth (Boston University) Medical Services, Boston City Hospital; assistant professor of medicine, Boston University School of Medicine.

The spleen weighed 260 gm. Its capsular surface was dark purple and wrinkled. Microscopically the features of congestion were prominent. Both adrenal glands were considerably smaller and thinner than normal, but showed no abnormality on microscopical examination. The uterus appeared smaller than usual; the left ovary contained two small cysts.

The vertebral bone marrow showed granulocytes in all phases of development; numerous stem cells were present.

FIGURE 1. *Appearance of the Patient in Case 1.*
Note the spots distributed thickly on and around the lips and sparsely over the bridge of the nose. Highlight in the photograph prevents the clear view of the spots on the fingers of the right hand.

There were moderate numbers of nucleated red blood cells and occasional scattered hemosiderin-filled macrophages.

Microscopical examination of the jejunal mucosa showed the tips of many villi to be club shaped and filled with macrophages containing large clumps of hemosiderin. Well differentiated adenomatous cells comprised the mucosal polyps.

CASE 2. A 39-year-old housewife of Italian-French descent entered the Boston City Hospital on October 22, 1939. For the previous 9 months she had noted increasing constipation requiring frequent enemas. In addition there was intermittent rectal bleeding. Twenty-four hours prior to entry, a mass, which was very painful and bled on attempts at replacement, protruded from the rectum.

Twenty years previously the right fallopian tube and ovary had been removed because of chronic pelvic disease. Five years before the final admission a cholecystectomy was performed after indigestion and pain in the right upper quadrant of the abdomen of 1 year's duration. Three years later the patient was observed in the hospital because of recent onset of anorexia, nausea and vomiting. A gastrointestinal x-ray series revealed irregularity of the stomach and displacement of the duodenal cap, interpreted as being due to postoperative perigastric and periduodenal adhesions.

The patient's parents and husband were living and well. She had had 4 miscarriages. There were 2 healthy children. A first cousin (Case 4) and this cousin's daughter (Case 5) both suffered from complaints referable to the gastrointestinal system. There was no familial tendency to freckles.

Physical examination revealed a well developed and fairly well nourished woman. There were numerous brown and bluish-brown pigmented spots on the face about the eyes and the mouth, on the lips and gums and on the fingers and toes. These averaged 1 to 3 mm. in diameter (Fig. 2). There was no pigmentation elsewhere on the body. The hair was black, and the eyes dark brown. The head was normal. The lungs were clear. The heart was not enlarged, and the rate was 80, with a regular rhythm and sounds of good quality. A soft systolic murmur was audible at the apex. There were no thrills or rubs. The abdomen was soft and not distended; in the lower abdomen there was moderate tenderness, and a poorly defined movable mass was palpated in the right lower quadrant. The rectum was found to be prolapsed and external hemorrhoids were visible. There was slight clubbing of the fingers.

The blood pressure was 108/70.

Examination of the blood showed a red-cell count of 4,160,000, with a hemoglobin of 85 per cent, and a white-cell count of 7500, with a normal differential count. The blood Hinton test was negative, as was examination of the urine. The stools were tarry black and gave a ++++ guaiac reaction. A gastrointestinal x-ray series revealed multiple polyps of the small and large intestine.

A series of operations was embarked upon: ileostomy, partial colectomy, fulguration of polyps in the rectosigmoid and anastomosis between the ileum and rectosigmoid. Initially, the patient showed some improvement, but after the last procedure there was considerable intraperitoneal and wound infection, and evidence of the development of a fecal fistula to the abdominal wall. She began to fail rapidly in weight and strength and died on March 14, 1940.

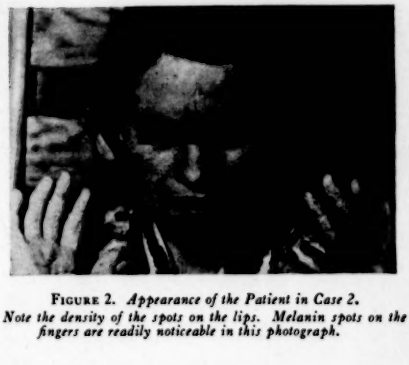

FIGURE 2. *Appearance of the Patient in Case 2.*
Note the density of the spots on the lips. Melanin spots on the fingers are readily noticeable in this photograph.

At autopsy pigmentation of the skin as previously described was noted. Examination of the pericardial cavity was negative. The heart was normal in size and weight. The aortic valve was slightly thickened; the right and posterior cusps were fused along the entire length of the commissure. The tricuspid valve contained only two well formed leaflets and appeared identical with the mitral valve. The foramen ovale and ductus arteriosus were closed.

Examination of the pleural cavity was negative. The lungs were of normal size and weight. The right lung contained an azygos lobe.

The peritoneal surfaces were grayish yellow, with a marked amount of thin, foul-smelling exudate. A pelvic abscess was found at the site of anastomosis of the ileum and rectosigmoid. The superior mesenteric artery originated from the celiac axis. The stomach contained a 1.0-cm. sessile polyp in the middle portion of the greater curvature; the mucosa was otherwise normal. In the duodenum the mucosa contained 10 pedunculated polyps varying from 0.8 to 2.0 cm. in diameter. The pedicles were from 0.5 to 3.0 cm. in length and all were approximately 3 to 5 mm. in thickness. There was 1 small polyp of the jejunum, and 8 in the ileum, all being pedunculated and varying in size as those described

in the duodenum. The entire mucosa of the small intestine was brown gray, giving the appearance of fish skin. The rectum contained several cherry-red fungating polyps, 2 or 3 cm. in size. The liver, spleen, kidneys and adrenal glands were normal.

Microscopical examination of the jejunal polyp showed it to be composed of acini of tall columnar cells, some of which were goblet cells, radiating from a fibromuscular pedicle.

CASE 3.* A 22-year-old woman was admitted to the Rhode Island Hospital, Providence, Rhode Island, on November 16, 1936, because of periodic abdominal pain of 3 months' duration consistent with the diagnosis of intussusception.

The family and past histories were irrelevant. No information about the duration of the oral pigment spots in the patient or their possible presence in her forebears was available.

Physical examination of the mouth and face revealed many small melanin spots on the lips and on the mucosa of the inside of the mouth (Fig. 3). Information regarding spots on the hands and feet was not available.

At operation an intussusception of the terminal ileum due to a polyp was found, and a hard mass in the small intestine about 30 cm. from the cecum proved to be an adenocarcinoma of the ileum. Resection of this lesion and side-to-side anastomosis were done, with good results and an uneventful

FIGURE 3. *Appearance of the Buccal Mucosa in Case 3. Note the size and distribution of melanin spots on the buccal mucosa. Those on the lips are readily seen despite the presence of lipstick. Relatively few are present on the skin about the mouth. (Photograph published through the courtesy of Dr. F. Ronchese, of Providence, Rhode Island.)*

recovery. Polyps of the stomach were said to have been present also.

The patient was seen periodically for follow-up study. In August, 1937, another operation was performed because intestinal obstruction was suspected. A band of tissue was excised. In January, 1939, she again had an episode suggestive of intestinal obstruction. In July, 1940, she was operated upon for recurrent abdominal pain. Large polyps were found in the stomach near the pylorus and in the ileum, and appropriate surgical therapy was applied. After this she was symptom-free for 2 months.

In November abdominal pain and obstructive signs recurred. At operation intussusception was seen, and polyps of the stomach, jejunum and ileum noted. In March, 1942, intussusception due to small-gut polyposis again necessitated operation; at this time the additional diagnosis of polyposis of the large intestine was added to the patient's record. At the last report in September, 1944, the patient was working regularly and free of complaints.

CASE 4. A 30-year-old housewife of Italian ancestry was admitted to the Boston City Hospital on November 2, 1935. She complained of mid-abdominal pain, intermittent and colicky, of 2 days' duration. Two years previously there had been two similar attacks, which had subsided spontaneously. There was a history of chronic constipation. Three years previously an appendectomy had been performed.

The family history was irrelevant, except for the occurrence of pigmentation of the face, similar to the patient's, in her

FIGURE 4. *Pigmentary Pattern Similar in Mother (Case 4) and Daughter (Case 5). Note the main distribution in each on and about the lips.*

father and her paternal grandmother, as well as in her own daughter (Case 5) and her first cousin (Case 2).

Physical examination revealed a well developed and well nourished woman who appeared acutely ill. The temperature was 99°F. There were numerous small brown-black pigmented areas on the lips, oral mucosa and nose (Fig. 4), and a few on the fingers and toes. The lungs were clear. The heart was normal. The blood pressure was 120/78. Abdominal examination revealed tenderness immediately above and to the left of the umbilicus, where a small, firm mass was intermittently palpable. There was no muscle spasm. The white-cell count was 15,000.

At laparotomy, performed shortly after admission, an intussusception of the ileum was readily discerned. This was reduced easily, and the darkened color of the intestine improved promptly. A small dimple was seen on the serosa of the ileum at the origin of the intussusception. At this point a mass was palpable within the lumen from which a walnut-sized polyp was excised. The patient made a prompt and satisfactory recovery postoperatively.

Examination of the surgical specimen showed it to consist of a soft, mucosa-covered papilloma with a small pedicle. The mucosa was intact and normal in appearance. The cut surface revealed a smooth, gray appearance. Microscopically, the specimen had the characteristics of a benign polyp.

CASE 5.† A 9-year-old girl of Italian ancestry was admitted to the Children's Hospital of Boston on December 10, 1937, with the complaint of abdominal pain.

For the previous 2 years the child had had recurrent bouts of severe, crampy abdominal pains localized at the umbilicus.

*Reported through the courtesy of Dr. Francesco Ronchese, of Providence, Rhode Island.

†This case and Figure 4 and 5 were made available through the courtesy of the Children's Hospital, Boston, Massachusetts.

They had never been associated with dietary indiscretions or irregularity of the bowels. The pains had been paroxysmal, lasting a few minutes and recurring in a few minutes, usually disappearing entirely after 1 or 2 hours. Occasionally, vomiting had been present with these episodes, but no bloody, tarry or mucus-containing stools had been noted. Typically, the patient was well immediately before and immediately after each attack, and on examination by various physicians and at outpatient clinics after an attack no abnormality had been found.

One hour before this hospital admission the patient again suffered a typical recurrence of crampy abdominal pain, which differed only in that it seemed much more severe than on previous occasions. Instead of disappearing, this pain kept recurring in stronger paroxysms every 1 or 2 minutes, making the child scream with pain. A few minutes after the onset of this illness she began to vomit bile-stained material. Nothing was passed by rectum.

FIGURE 5. *Close-up Photograph in Case 5, Showing the Density of the Melanin Spots on the Lips and about the Mouth.*

The patient had been a full-term, normal baby. She had been examined on several occasions in the Outpatient Department during the preceding 3 years for attacks of bronchitis and after previous attacks of abdominal pain. The past history was otherwise noncontributory. Her parents were living; the mother (Case 4) had undergone an abdominal operation for intussusception 2 years previously. One brother, 8 years of age, was living and well. Another sibling had been born dead 11 years previously. The patient's mother, and the latter's father and paternal grandmother had all had similar pigmentation of the face about the mouth. Unfortunately, information concerning polyposis in these ancestors was unobtainable.

Physical examination revealed an acutely ill girl. There were numerous blue-brown to black small spots on the face, concentrated about the mouth and on the mucosa of the lips and mouth (Fig. 4 and 5). The hair and irides were dark brown. Examination of the heart and lung was negative. The abdomen was not distended, but there was moderate fullness in the left upper quadrant. No direct spasm could be elicited, but intermittently there was tenderness over a transiently palpable tumor in the left upper quadrant. This tumor appeared to be fairly movable in all directions and measured 10 by 5 cm. The liver edge was felt 1 cm. below the costal margin. Rectal examination was negative. The white-cell count on entry was 20,150.

Shortly after examination a laparotomy was performed. A jejunoileal intussusception was promptly noted and was reduced. A walnut-sized tumor could be palpated at the site of intussusception, and on opening of the intestine a polyp was removed. *Staphylococcus aureus* septicemia, with pneumonia, empyema and peritonitis developed, and the patient died on January 2, 1938.

At autopsy, in addition to the pigmentation previously noted, there was a generalized petechial eruption. Bilateral bronchopneumonia and empyema were present. The abdominal cavity contained a large amount of brown fluid. The mucosa of the stomach was thrown up into prominent longtitudinal rugae, and on the tips of these rugae four polypoid formations were noted. These varied from mere mucosal elevations to one pedunculated polyp 2 cm. in diameter; they were pinkish white and slightly lobulated. The entire small intestine contained numerous polyps of varying size, most of them about the size of a pea and many with pedicles, but occasional ones showing a sessile type of base. These were attached to the intestinal villi. The appendix was 10 cm. long, with a reddish-black, bulbous tip. It was retrocecal in position and bound down in an appendiceal abscess. There was no abnormality of the large intestine. The mucosa of the rectum contained a polyp about 2 cm. in diameter. A total of twenty polyps of the gastrointestinal tract were counted. The adrenal glands were normal in shape and consistence; the cut surface revealed a normal architecture. There were multiple small cysts of the left ovary, approximating 2 or 3 mm. in diameter, and filled with clear, yellow fluid.

Examination of the polyp removed at operation showed it to be 4.3 by 3 by 1.8 cm. Cut section revealed a circular core, which was composed of tough connective tissue. Surrounding this was an abundant amount of glandular tissue. The mucosal epithelium was normal histologically. The lamina propria was markedly vascular, and there was extensive inflammatory cell infiltration consisting about equally of neutrophilic and eosinophilic polymorphonuclear leukocytes, plasma cells and mononuclear cells. At no part of the specimen was there any evidence of cancer.

CASE 6. A 16-year-old Negro boy born on the Outside Obstetrical Service of the Johns Hopkins Hospital had been observed throughout his life at frequent intervals in the various outpatient clinics and on the wards of the Johns Hopkins Hospital.

As far as could be determined, the family history was negative for bowel difficulties and for pigmentation of the type under discussion.

The patient had suffered all his life from complications attributed to intestinal polyposis. At the age of 8 months rectal prolapse with a visible polyp had occurred. This recurred repeatedly in spite of removal of several polyps — described grossly and histologically as "papilloma of the rectum."

At the age of 6 years, the boy began to have attacks of periumbilical pain about once a month. In 1946 he was admitted to the hospital for intussusception. A laparotomy was performed by Dr. H. William Scott, Jr. An ileocolic type of intussusception was found. Taxis was unsuccessful. Resection of the ascending colon, half the transverse colon and the ileum back 30 cm. from the beginning of the intussusception was performed. The ends of the colon and ileum were exteriorized by the Mickulicz technic and later closed. Two polyps were noted in the ileal portion of the operative specimen. There was no sign of melanosis coli in the specimen.

At the third admission, on June 11, 1947, because of dizziness and shortness of breath on exertion, the patient's diet was found to have been unusually inadequate, having consisted largely of candy and soft drinks. Physical examination revealed pallor and blowing systolic murmurs at the apex and in the pulmonic area. Examination of the blood disclosed a red-cell count of 3,420,000, with a hemoglobin of 4.3 gm., and a hematocrit of 19 mm., giving a mean corpuscular volume of 56 cubic microns, a mean corpuscular hemoglobin of 13 micromicrogm. and a mean corpuscular hemoglobin concentration of 23 per cent.

The stools gave negative to ++++ guaiac tests. No parasitic ova or cysts were identified. Preparations for sickling were repeatedly negative. After a detailed gastrointestinal study it was finally concluded that the patient probably had polyps somewhere in the alimentary canal, which our imperfect methods could not demonstrate, and that bleeding from these, together with a grossly inadequate diet, was responsible for the anemia. Lack of absorptive surface as a result of extensive intestinal resection was a possible additional factor. On iron therapy the reticulocytes rose to a peak of 12.8 per cent.

It was on this admission that attention was called to the pigmentary peculiarities and studies thereof were made. On the outside of both lips and extending onto the skin about 1.5 cm. from the vermilion border there were darkly pigmented spots of irregular outline and size varying from that

of a pinhead to 2 mm. in the largest dimension (Fig. 6). They covered the vermilion portions and the entire dental surfaces of the lips. There were a few similar spots on the buccal mucous membranes and lateral edges of the tongue. On the mucous membrane covering the posterior commissure of the upper and lower jaws there was on each side a prominent spot measuring about 4 mm. in diameter (Fig. 7). The general color of the skin was a very light tan. In the "butterfly area" of the face there were also a few spots resembling those on the lips (Fig. 6). There was a fleck of pigment in the bulbar conjunctiva of the right eye at the limbus at 8 o'clock, and a similar but small spot on the conjunctiva of the left eye at the limbus at 4 o'clock. Funduscopic examination revealed nothing remarkable. On the hypothenar

FIGURE 6. *Appearance of the Patient in Case 6.*
The characteristic dense localization of spots on the lips, more marked on the lower lip, is well demonstrated. Note the relative paucity of spots elsewhere on the face.

eminence of the right hand there was a pigmented spot 5 mm. in diameter. On both index fingers were numerous dots, and under the nail of the left index finger at the point a pigmented area (Fig. 8). There was a pigmented macule on the sole of the left foot. Otherwise the body was essentially free of any localized areas of increased pigmentation. All the areas described were not elevated and were perfectly smooth.

These areas of pigmentation had been present as long as the patient or his mother could recall and had not changed. Unfortunately, no photographs from infancy or childhood were available. One brother and 2 half sisters did not show the anomaly. None of the mother's family showed it; the father's family lived in a distant state and was not available for observation.

On May 25, 1948, the patient was admitted again with intussusception. On that date a laparotomy was performed by Dr. Marshall C. Sanford. Two groups of polyps were palpated in the small intestine: one in the upper jejunum just below the ligament of Treitz, the region being intussuscepted into the jejunum below for a distance of 21 cm., and a second group of polyps approximately 61 cm. distal to Treitz's ligament. The jejunum was resected from the ligament of Treitz to below the second group, and an end-to-end

FIGURE 7. *Photograph Demonstrating Melanin Areas Inside the Mouth in Case 6.*

duodenojejunostomy performed. At this laparotomy a polyp was felt in the descending colon, and another in the sigmoid about 15 cm. below the first. After proper prepara-

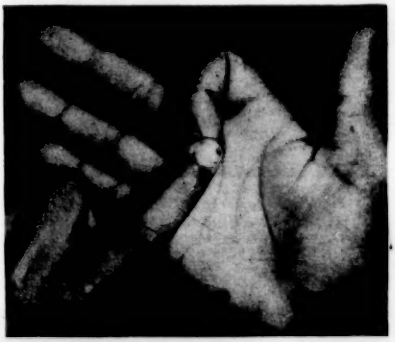

FIGURE 8. *Photograph of the Right Hand in Case 6.*
Melanin spots are present on the palm and thumb and especially on the forefinger.

tion of the bowel with sulfasuxidine, a 15-cm. length of the left colon, including the polyps, was resected as a separate procedure on June 7. The polyps were grossly and microscopically identical with those previously removed.

CASE 7.* A 15-year-old girl had previously been admitted to the Johns Hopkins Hospital in 1937 at the age of 6 years. Eighteen months before that admission the patient had become rundown, pale and anorexic. One year before admission tarry stools were occasionally noticed, and there was the onset of dull abdominal pain present each morning on awakening. This daily morning pain continued until the time of the first admission, and, in addition, there was occasional nausea and vomiting. Sometimes, the pain required morphine for relief. During severe attacks it radiated to the left lower quadrant, where there was said to be a visible mass, and gurgling sounds were audible across the room. The stools were guaiac positive on numerous occasions, and the hemoglobin at one time was 30 per cent of normal.

On admission in 1937 the physical examination was recorded as essentially negative, and the diagnostic impression was Meckel's diverticulum. The spots in the mouth were described, but their diagnostic significance was not appreciated. Two days after admission the patient was seized with severe abdominal pain, which caused her to scream and clutch her abdomen. This was associated with continuous retching. On laparotomy 2 ileoileal intussusceptions and 3 polyps were discovered. The first intussusception was 45 cm. above the ileocecal valve and was easily reduced. A polyp was palpated at the head of the intussusceptum and was removed by elliptical resection. About 76 cm. above this intussusception was a second, larger one, which on reduction was found to be an intussusception within an intussusception with a polyp as the cause of each invagination. These polyps were similarly resected. No others were found.

FIGURE 9. *Appearance of the Patient in Case 7.*
Note the spots on the lower lips and on the buccal mucosa. Spots are also visible on the mucosa just inside the nostril. Spots on the upper lip are relatively sparse.

The patient did well until the following spring, when she had an acute attack of abdominal pain and was operated upon in a South Carolina hospital, where adhesions were reported as the only finding. Thereafter she was well until 1946. During the next year there was a gradual loss of appetite, development of weakness and a loss of about 6 pounds of weight. Two months before this admission the old crampy abdominal pain recurred, lasting from 1 to 12 hours at a time. In the 2 weeks before admission in October, 1947, a steady drop in hemoglobin to 60 per cent was observed. There was considerable nausea but no vomiting. Two days before, the patient had pain all day associated with considerable nausea but no vomiting.

On admission the physical findings were not remarkable except for the pallor (the hemoglobin was 9 gm.) and the spots described below. There was no digital clubbing. The stools were brown and formed, but guaiac positive. Sigmoidoscopic examination, performed by Dr. J. T. Howard, revealed 2 polyps in the lower sigmoid, 1 "the size of a peanut and the other the size of a hazelnut." A gastrointestinal series revealed negative filling defects in the stomach suggestive of polyps. Studies of the small intestine were performed by the passage of barium and then air through a Miller–Abbott tube inserted for the proper distance. By this method several areas suspicious of polyps were visualized. A barium enema by the routine technic and without injection of air was negative.

At operation, performed on October 31 by Dr. I. R. Trimble, the stomach was opened, and 2 polyps were found on the greater curvature in the lower portion of the organ. The larger of these measured about 2 cm. in diameter. The entire length of the small intestine was carefully examined by means of palpation and transillumination. In the distal jejunum and proximal ileum several polyps were palpated, and about 122 cm. of this portion of the gut was resected. This specimen contained 8 large pedunculated polyps, the largest of which measured about 25 cm. in diameter. Histologic examination revealed these structures to be typical benign polyps. Several polyps could be palpated in the transverse colon (the only portion of the large intestine in the operative field), but no operative procedure was attempted in connection with them.

The patient was an only child. Absolutely no history of gastrointestinal disturbance could be elicted among her forebears, nor had any of them, including the parents, shown a pigmentary anomaly resembling the patient's. These spots had been noted almost from birth. There was no family history of freckles. The mother had a photograph of the patient at the age of 3 months showing them quite distinctly. These spots were numerous on the vermilion border and on the dental aspect of the lips. They were perfectly flat areas of hyperpigmentation of irregular outline and variable size. On examination with a magnifying glass some of the spots had a somewhat stippled appearance. Spots of the same description were present on the buccal mucous membrane (Fig. 9) bilaterally, but none were seen on the tongue. There were several light spots over the palms and fingers, and there were a few on the feet. The remainder of the body was completely free of any unusual type of pigmentation. No freckles were present — in fact, the skin of the face was exceptionally free of all blemishes except the melanin spots described above.

CASE 8.† A 27-year-old man, second in a family of five the genealogy of which is shown in Figure 10, was a brother of the patients in Case 9 and 10. He was born in 1921. From an early age he has been subject to frequent, in fact almost daily, "bellyaches," especially after eating. Over the course of about 18 months, in 1938 and 1939, at the age of about 17, he had had some very severe attacks of crampy, intermittent abdominal pain, for which he was admitted to the Harrisburg Hospital on several occasions. Each time, the pain disappeared spontaneously, and no satisfactory diagnosis was arrived at. Finally, the possibility of intestinal polyposis, with intussusception, was proposed by Dr. C. E. Moore, who performed a laparotomy on December 18, 1939. At that time an easily reducible intussusception in the upper portion of the jejunum was discovered, and multiple soft masses could be felt in its lumen. About 150 cm. of jejunum was resected, extending from 10 cm. below the ligament of Treitz to below the area where polyps could be felt. End-to-side anastomosis was necessary because of luminal disproportion. The specimen removed was described by the pathologist as showing 30 soft, lobulated polyps. Microscopically, they were the usual adenomatous polyps.

Early in 1945, attacks of crampy abdominal pain began, mainly on the right, increasing in severity and frequency over the course of 3 months. On January 16, 1948, because of these increasingly severe attacks, laparotomy was per-

*This case is reported with the permission of Dr. I. R. Trimble. A report of this case is included in the paper by Ravitch[18] dealing with polypoid adenomatosis of the entire gastrointestinal tract.

†Case 8, 9 and 10 are reported through the courtesy of Dr. C. E. Moore, of Harrisburg, Pennsylvania.

formed. Two intussusceptions were discovered. The first was 90 cm. proximal to the ileocecal valve, with telescoping of the bowel for 10 cm. At the head of the intussusception was a thumb-sized polyp, which was removed by simple elliptical incision. The second intussusception was ileocolic in type and had its cause, again, in a small polyp the size of an English walnut. This was removed in a similar manner. A very careful examination of the entire gastrointestinal tract was made. No evidence of polyps was found in stomach, duodenum or jejunum, and on this occasion none could be felt in the colon, including the transverse colon, where it was thought that a solitary one had been felt in 1943. Histologically, the polyps were not remarkable.

After this operation the patient was asymptomatic up to the time when he was examined by one of us. He was found to be a very muscular young man, perhaps slightly overweight. There was no evidence of anemia. The eyes were dark blue, and the hair brown black. The only unusual feature of the examination was the presence of gray pigmented spots on the vermilion border of the lower lip identical with those in the other cases. The spots were concentrated somewhat toward the commissure on either side. There were no spots on the dental aspects of the lips, but on the buccal mucosa in the region of the posterior commissures of the jaw, and in juxtaposition to the lower teeth there were small, irregular spots, which had a definite stippled appearance on magnification. There were two spots, likewise stippled, on the hard palate. (These spots had been noted from the first by Dr. Moore, who speculated on their possible relation to the intestinal polyposis). The face, which was deeply sun-tanned, was essentially free of freckles. The hands were rough and calloused, but a few small, brown-gray spots were seen on both dorsal and volar aspects of the fingers. The spots on the lips had been present and unchanged as long as the patient could recall.

Case 9. The sister (born in 1924) of the patients in Case 8 and 10, was 4th in a family of 5, the genealogy of which is shown in Figure 10. Through early adolescence the patient had suffered from recurrent attacks of crampy abdominal pain accompanied at times by vomiting. There was never melena or fresh blood in the stools, and she was never noticeably anemic. At the age of 16, because of this history and because of the previous discovery of polyposis in a brother (Case 8), she was admitted to the Harrisburg Hospital, and laparotomy was performed on June 28, 1940, by Dr. C. E. Moore. The upper 91 cm. of the jejunum was found to be somewhat dilated, and many firm nodules were palpated in its lumen, the most proximal one being about 8 cm. below the ligament of Treitz. No intussusception was present at the time of laparotomy. The stomach, duodenum, ileum and colon appeared to be normal. The proximal 90 cm. of the jejunum was resected, and the continuity was restored by a lateral anastomosis. The specimen was found to contain 5 polyps, the largest measuring 3.5 cm. in length and 2.2 cm. in diameter. Histologically, they were the usual polypoid adenomas.

After operation the patient was asymptomatic. When examined by one of us in 1948, she was well developed and adequately nourished without evidence of anemia. She was somewhat darker in complexion than her brothers. The hair was black, and the irides dark brown. The only unusual feature of the physical examination consisted of dark, pigmented spots on the vermilion border of the lower lip, with a few smaller ones on the cutaneous portion of the lower lip. Those on the vermilion border were quite deeply pigmented and prominent, and only imperfectly concealed by lipstick. In the mouth there were 2 spots on the left buccal mucosa, 3 on the right and a single small pigmented area on the hard palate. All these areas had a definitely stippled appearance. There were a few spots in the butterfly area of the nose and

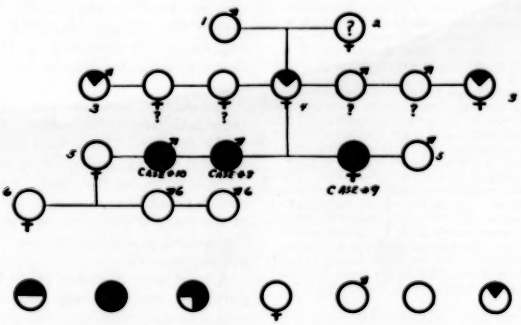

Figure 10. *Genealogic Table of Harrisburg Family with Pigment Spots and Polyposis. (Data Provided through the Courtesy of Dr. C. E. Moore.)*

Key: Blank circle = normal. One-fourth circle = pigmentation not looked for; probable polyposis. One-half circle = pigmentation; no polyps clinically. Three-fourths circle = pigmentation and probable polyposis. Full circle = pigmentation and proved polyposis.

1. *Death from cancer of pancreas at age of sixty-nine. No pigmentation or intestinal polyps at autopsy.*
2. *No information available except death from "heart attack."*
3. *Death from "intussusception" in second decade of life. No information about pigmentation.*
4. *Death from "cancer of intestine" at age of forty. No information about pigmentation.*
5. *No history of pigmentation or intestinal trouble. Not available for examination. (See footnote under Case 10.)*
6. *No history of pigmentation or intestinal trouble. Not available for examination. (See footnote under Case 10.)*

?No information available.

cheek. On both the dorsal and volar aspects of the fingers were a number of brown spots. The remainder of the body was free of unusual pigmentation.

CASE 10. The brother of the patients in Case 8 and 9 and 2nd in a family of 5, the genealogy of which is shown in Figure 10, experienced, at about the age of 20, recurrent attacks of mid-abdominal pain occurring especially between 1 and 2 hours after eating and occasionally accompanied by vomiting. The attacks increased in severity and frequency over the course of the next 2 years. In 1942 he was admitted to the Harrisburg Hospital with a particularly severe attack of this description of 2 days' duration. An indefinite tumescence was observed in the region of the umbilicus. At laparotomy, performed on February 16, by Dr. C. E. Moore, an intussusception was found in the jejunum about 76 cm. below the ligament of Treitz. This was quite easily reduced. At the head of the intussusception a polyp was palpated, and several others were felt in the jejunum to a distance of 122 cm. from the ligament of Treitz. The stomach, duodenum, ileum and colon felt normal. The jejunum was resected for a distance of 122 cm., beginning at a point 15 cm. below the ligament of Treitz. Lateral anastomosis was performed, the continuity of the bowel thereby being reestablished.

After operation the patient had been completely asymptomatic up to the time he was examined by one of us in 1948. At that time he was found to be a very muscular, slightly overnourished young man with good color and a striking resemblance to his younger brother. The hair was dark brown, and the irides dark blue. In this case, the pigmentation of the lips was the least marked of any of the siblings. There were, however, over the vermilion border of the lower lip, 10 or 12 small dark-brown, pigmented spots concentrated mainly near the commissure on either side. Inside the mouth there were 2 or 3 pigmented spots with a stippled appearance on the buccal mucosa on each side. There was no pigmentation of the hard palate. The face was deeply tanned, but essentially free of freckles. The hands were calloused and roughened, but showed a few spots on the fingers.*

REVIEW OF THE LITERATURE

Interest in this syndrome was first aroused when a patient (Case 1) was seen on the Fifth Medical Service of the Boston City Hospital in 1939 during a study of the association of skin pigmentation with systemic disease.[1] Dr. Chester S. Keefer, who had seen the patient on ward rounds, commented later, in a personal communication, on the similarity of this girl's pigmentation to that of twins in the cases reported by Sir Jonathan Hutchinson[2] in 1896. This report concerned twelve-year-old twins (Fig. 11) with an anomaly described as follows:

> . . . a number of black pigmented spots on the lips and inside of the mouth. It was at the age of three that these spots had first been noticed, and the evidence was definite that none had been present at birth. The spots had increased in number and size at exactly parallel rates in the two, and the conditions presented were just the same in each.

FIGURE 11. *Identical Twins, Each with Melanin Spots on and about the Lips and on the Buccal Mucosa, as Shown in the Small Insert. (Reproduced from Hutchinson.[2])*
Note the similarity of distribution of pigment spots in these cases with those reported in this paper.

No note is made of the presence or absence of pigmented areas on the hands. The striking resemblance between the pigmentary pattern in Case 1 and the twins described by Hutchinson is clearly demonstrated by comparison of Figure 1 and Figure 11.

Hutchinson was not aware of the presence of any intestinal trouble in either of the twins, for he wrote further: "That they [the pigmented spots] are not in any active sense pathological we may safely assure, for they appear to be not aggressive, and their subjects remain in good health." Because of the marked similarity of the process in the twins Sir Jonathan considered the pigmentation a congenital anomaly.

A brief note on these twins had previously been published by Connor,[3] who contributed the significant additional information that the twins were "of dark complexion and anemic." The pigment spots were described as being "of very small size and scattered over the lips (especially the lower), gums and hard palate, but not on the tongue."

The patient in Case 2 was seen at Boston City Hospital later in 1939 and because of similarity to Case 1 was likewise photographed and studied. This second case strongly suggested that this distinctive type of pigmentation in combination with intestinal polyposis was not a fortuitous association but was probably of related significance.

A limited search of the literature at that time revealed a paper by Weber,[4] who in 1919 reported a follow-up study on Hutchinson's cases. He stated that the spots apparently had not enlarged. However, the most interesting portion of his follow-up observation was this: "One of the twins died at the age of twenty years, from intussusception, at the Metropolitan Hospital (London), but the other (B. H.) is still living and is in good health, now (1919) aged thirty-five years." The Metropolitan Hospital[5] has no record that an autopsy was performed, a point confirmed by Weber.[6] However, from a copy of the death certificate obtained for us by Dr. L. Forman, British dermatologist, it is known that an operation for intussusception with resection of the gut was performed and that the patient died of "septic pneumonia and pleuritis." Although not specifically stated there is a strong possibility that intestinal polyposis was the cause of the intussusception in the

*On January 22, 1949, the youngest member of this Harrisburg family, a 21-year-old man, died a few days after admission to another hospital for an acute abdominal episode. Two operations were performed at which intussusception due to polyp of the small intestine was discovered. The brothers and sisters of this patient stated that he showed no pigmented spots, but he was actually not examined by us.

first twin. A recent personal communication from R. H. (a living brother of the twins) states that the second twin died at the age of fifty-two of cancer of the breast. He could supply no data concerning intestinal symptoms. She died at home, and no autopsy was performed. Weber[4] noted no pigmentation in the other members of the twin's family, a point corroborated by the brother, R. H.

Case 3 was called to our attention by Dr. Francesco Ronchese, of Providence, Rhode Island, after publication of the preliminary note concerning Case 1 and 2.[1]

The patient in Case 4, a first cousin of another patient (Case 2), and still alive, came to our attention when relatives of the latter were questioned

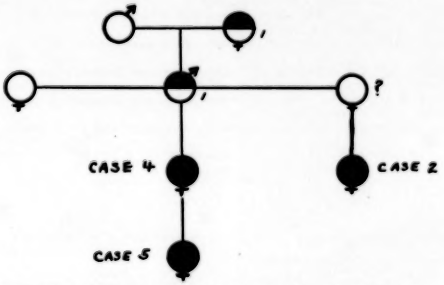

FIGURE 12. *Genealogic Table of Boston Family with Pigment Spots and Polyposis.*

1. *Known to have characteristic pigmentation. No information about polyposis available.*
?*No information available.*

about her family history. She had been admitted to Boston City Hospital in 1935. Adequate data were available in this record.

The patient in Case 4 gave the details for assembling the pedigree of the syndrome in this family (Fig. 12) and led to knowledge of her daughter (Case 5), who had died at the Children's Hospital, Boston, Massachusetts, in 1938.

Case 6 and 7 were noted by one of us at the Johns Hopkins Hospital within a few months of each other.

Case 8, 9 and 10 are patients of Dr. C. E. Moore, of Harrisburg, Pennsylvania, who, hearing of our interest in this syndrome, called them to our attention and permitted one of us to examine them.

The finding of 10 patients with this syndrome stimulated us to a more thorough search of the literature than the one made in 1944, when Case 1 and 2 were reported briefly.

Apparently the first specific reference in the medical literature concerning this disorder and the earliest to stress the association of pigmentation and intestinal polyposis by a specific title is a paper by Peutz,[7] of The Hague, who, in 1921, described a family in which several members had pigment spots of the mouth, hands and feet with intestinal polyposis. Reference to this paper is made by Meirowsky,[8] and the article is also listed in the *Index Medicus* but was overlooked in our earlier, limited search.

No other title under the heading of intestinal polyposis with pigmentation was found in the *Quarterly Cumulative Index Medicus* or *Index Medicus* prior to 1945. Metzger, Ohlmann and Halff,[9] under another title, reported a case of polyposis with a diffuse type of generalized melanin pigmentation that did not resemble the appearance in our cases. No mention of this syndrome was found in a representative group of standard textbooks on gastrointestinal disease, or in the standard dermatologic textbooks in English. This does not exclude the possibility that representative cases are reported under titles that would not suggest this syndrome.

As previously stated Peutz,[7] of The Hague, in 1921, described a family in which several members had pigmented spots of the mouth, hands and feet. Dr. Peutz[10] has very kindly supplied us with further information on this family, permitting the construction of the fabulous family tree shown in Figure 13. The cases cover three generations, with seven proved cases of the syndrome (intestinal polyps and spots), 1 suspected case and 1 person who presented the pigmentary anomaly without proved polyposis. Two of the family had nasal polyps in addition to the intestinal polyps, and 1 also had bladder polyps.

Figure 14 demonstrates the spots on the dental aspect of the lower lip in 1 of the cases (No. 7 in

Figure 13), together with the operative specimen from the ileum showing polyps. Although the face was more extensively involved in each of these

The first soot-coloured or dark-brown skin and lip pigmentation gradually faded in the course of years and even disappeared for the greater part between the ages of twenty-five and thirty; the spots got at least much

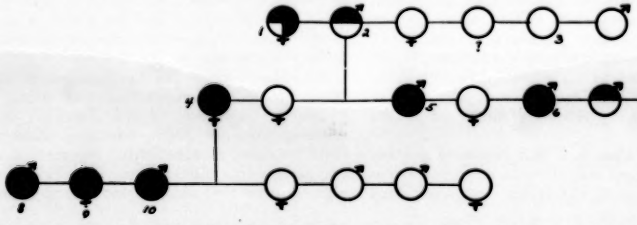

FIGURE 13. *Genealogic Table of Dutch Family with Pigment Spots and Polyposis. (Based on Data of Peutz.*[7,10])

1. *A nun — died of intestinal disease. History suggestive of polyposis. Had characteristic pigmentation.*
2. *Had characteristic pigmentation. Not studied for presence or absence of polyposis.*
3. *Died at age of four. No information available.*
4. *Several abdominal operations for intestinal polyposis. Died with ileus in 1937. Had characteristic pigmentation.*
5. *Had the pigmentation. Died with ileus in 1947. Malignant degeneration of intestinal polyps at autopsy.*
6. *Had the pigmentation. Died with ileus in 1948. Malignant degeneration of intestinal polyps at autopsy.*
7. *Case reported in detail by Peutz*[7] *in 1921. Intestinal polyps and characteristic pigmentation. Malignant degeneration diagnosed on surgical specimen.*
8. *Died of ileus in 1940. Polyps previously proved by rectoscopy and x-ray studies. Had characteristic pigmentation.*
9. *Had polyposis of intestine and characteristic pigmentation.*
10. *Had polyposis of intestine and characteristic pigmentation.*

cases than in our series the pigmentation of the lips and oral mucosa is identical. The extensive facial pigmentation is similar to that in the cases of Foerster[11] and Siemens[12] referred to below.

FIGURE 14. *Surgical Specimen and Appearance of Patient in a Case of Pigment Spots and Polyposis. (Reproduced from Peutz*[7] *with the Permission of the Publisher.)*

On the left is a resected portion of the small intestine, showing polyps. On the right is a photograph of the patient showing pigment spot on the lips and face. Note that the spots on the face in this patient were much more numerous than those on the face in the cases reported by us.

Regarding changes of the pigmentation with aging of the subject, Peutz[10] has the following interesting comment:

smaller . . . *The rectal and mouth pigmentation did not undergo this fading and becoming smaller* [italics ours].

Foerster[11] and Siemens[12] have described a total of 5 cases demonstrating extensive spotty pigmentation of the skin, lips and oral mucosa. Four of the cases were in members of the same family. Although the distribution of pigment on the lips, oral mucosa and digits resembled that in our cases, the pigmentation on the skin was much more extensive. Furthermore, these patients were studied only from the dermatologic standpoint, and any evidence of intestinal polyposis, if present, was not included in the reports. It is not clear therefore, whether these patients fall in the group studied by Peutz and ourselves.

Foerster[11] suggested that this pigmentary anomaly may represent an atavism. Siemens[12] referred to the spots as "ephilides inversae" because they are located where freckles are not seen at all or are only very sparse. Siemens's terminology aptly fits the distribution of the pigment spots in the cases of Peutz and ourselves.

To some slight extent the syndrome may have been known in Germany. In Jadassohn's *Handbuch*,[8] Meirowsky, in commenting on Peutz's cases, stated: "Professor Bruno Kisch has observed a case which belongs in this group; there were pea-sized spots of the gums; the father had died of ileus; the grandfather had succumbed to obstipation." Unfortunately no further details can be

obtained from Kisch,[13] who reports that his original notes are no longer available. However, he confirmed the validity of the statement of Meirowsky.

Four proved and 2 probable cases of this syndrome came to our attention while we were reviewing the quite limited literature of familial adenomatosis of the small intestine.

In 1924 van Dijk and Oudendal,[14] from Weltevreden in the Dutch East Indies, reported the cases of a sixteen-year-old Indo-European boy and his twenty-five-year-old sister, both of whom suffered from repeated colicky attacks. During severe attacks both were submitted to laparotomy and found to have intussusception of the ileum due to adenomas. Both patients showed pigmented spots of the lips, which had been present from birth and which resembled those found in our patients. The authors did not mention Peutz's publication of 1921 and did not stress the significance of the association of pigmented spots and intestinal polyposis.

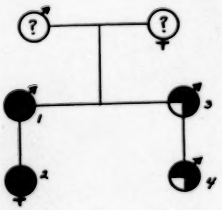

FIGURE 15. *Genealogic Table of a Welsh Family with Pigment Spots and Polyposis. (Based on Data of Foster.*[14, 15])

1. *Forty-three-year-old silversmith with spots and a proved polyp of the ileum.*
2. *Fifteen-year-old girl with spots and a proved polyp of the ileum.*
3. *Had the characteristic pigmentation and passage of blood and mucus by rectum. Inoperable carcinoma of the stomach developed.*
4. *Has the characteristic pigmentation as well as frequent attacks of colicky abdominal pain with passage of blood and mucus.*

?No information available.

In 1944 Foster[15] reported the cases of a forty-three-year-old silversmith and his sixteen-year-old daughter who presented themselves at the Llandough Hospital in Cardiff, Wales, within three years of each other with intussusception, which on laparotomy was found to be due to a single polyp. Foster stated: "It was noted that both patients presented a diffuse brownish pigmentation of the lips and face." No further comment was made of the pigmentation. In reply to our inquiry Foster[16] generously sent us a photograph of the daughter. The identity with the other cases is unmistakable.

In his report Foster[15] stated: "On investigating the family history it transpired that the father's brother showed similar pigmentation, and he had been a patient in this hospital in 1935 complaining of attacks of abdominal pain, with the passage of blood and mucus per rectum." The subsequent course of events was as follows[16]: "This man was admitted to a nearby hospital in Cardiff during 1947 and laparotomy then showed an inoperable carcinoma of the stomach . . . no further history is obtainable at the moment."

Foster[16] supplied information on a fourth very likely case of the syndrome in this Welsh family:

> [The son of the patient just described] . . . was admitted to Llandough Hospital on the 7th of October 1944, as a case of Addison's disease apparently on account of the pigmentation of the lips, oral mucous membrane, and palate. A history of attacks of abdominal pain of a colicky nature, occasionally severe and associated with the passage of blood and mucus per rectum over a period of about nine months was obtained. Since then he has had occasional attacks of abdominal pain with the passage of some mucus per rectum. . . .

FIGURE 16. *Appearance of a Patient with Melanin Spots. (Reproduced from Touraine and Couder*[18] *with the Permission of the Publisher.)*

This illustration clearly depicts the appearance of the melanin spots on the mucosa of the mouth.

Sufficient data were supplied by Foster for us to assemble a genealogic table for this family (Fig. 15).

The only other report of the complete syndrome was made by Touraine and Couder,[17] of Paris, in 1945, under the title "Syndrome of Peutz," and elaborated upon in 1946 under the title "Lentiginose péri-orficielle et polypose viscerale."[18] Their

patient was a fifteen-year-old girl with pigment spots of the lips and buccal mucosa (Fig. 16). The parents and a single sister were normal. In addition to the typical pigmentation, the patient had habitual constipation and occasional rectal prolapse with defecation. Rectal examination revealed an "enormous dilatation of the rectal ampulla and of the sigmoid; 7 cm. from the anus there was a mobile polyp, the size of a large nut, which, on biopsy, was a simple adenoma with great dilatation of the glandular cavities but without neoplastic transformation." A study adequate to exclude small-bowel polyposis was not made so that one can only speculate on its possible existence.

Touraine and Couder[18] collected from the literature 31 cases of pigment pattern identical with that in the case described by them, by Peutz and by us. The term "lentiginose péri-orificielle" was used to describe the pigment portion of the syndrome. These cases occurred as follows: 22 cases were familial; 8 occurred in three generations (Peutz[7]); 5 in four generations (Siemens[12]) and 9 in three generations (Ferrari[19]). Our original report of 2 cases was apparently not available to Touraine and Couder and not included by them in this tabulation. (Its publication in a paper under the general title "Pigmentation of the Skin" made recognition through the index listing difficult.) They likewise were not aware of Foster's[15] cases or those of van Dijk and Oudendal,[14] probably because of the misleading titles of these two papers. As listed in this tabulation only the 4 cases of Peutz[7] and possibly the one reported by Touraine and Couder[17, 18] had the full syndrome.

It is of interest that in these various reports of the pigment pattern collected by Touraine and Couder[18] 3 patients had data suggesting polyposis. Belote[20] reported at a dermatologic meeting the case of a twelve-year-old boy with the characteristic pigmentation who complained of bleeding from the rectum and increasing weakness; tarry stools had been present occasionally, and examination of the blood demonstrated secondary anemia. No further data on studies of the gastrointestinal tract were given. Because of the death of Dr. Belote it was impossible to trace this case further.[21]

In 1912, Crouzon and Chatelin[22] reported a case of the pigmentation in an eighty-three-year-old woman on the service of Pierre Marie at the Salpêtrière. In addition to the identical pigmentation, the patient was said to suffer from "rather frequent attacks of diarrhea (once or twice a month), not accompanied by vomiting."

The remaining suspected case of the syndrome was reported by Hudelo and Rabut[23] in 1927. Their patient manifested the characteristic pigmentation and in addition was said to have suffered from "indigestion, abdominal pains and nausea." Histologic study of a biopsy specimen revealed the pigment to be melanin.

TABLE 1. *Cases of Intestinal Polyposis and Pigmentation.*

TYPE OF CASE	AUTHOR	REPORTED IN LITERATURE	REPORTED BY PERSONAL COMMUNICATION
		NO. OF CASES	NO. OF CASES
Proved	Peutz[7, 18]	4	3
	van Dijk and Oudendal[14]	2	
	Foster[15]	2	
	Touraine and Couder[17, 18] (only rectal polyps identified)	1	
Probable	Twin described by Hutchinson[24, 6] (E. A. H.)		1
	Peutz[7, 18]	2	
	Foster[15, 25]	1	1
Possible	Twin described by Hutchinson[24, 6] (B. H.)	1	
	Crouzon and Chatelin[22]	1	
	Hudelo and Rabut[23]	1	
	Belote[20]	1	
Totals		16	5

FIGURE 17. *Photograph of a Fifty-Seven-Year-Old White Woman Who Had Melanin Spots of Lips and Mucous Membrane of the Mouth but in Whom Polyps of the Stomach or Colon Were Not Demonstrated.*

This is a possible case of pigmentary portion of the syndrome without polyposis.

The proved, probable and possible cases recorded in the literature or described in personal communications are summarized in Table 1.

Although one of us has been looking for such cases for the past eight years, we have personally encountered only 1 case in which a pigment pattern indistinguishable from that of the syndrome being discussed in this paper was noted in a person in whom polyposis could not be demonstrated. A brief report of this case* is as follows:

C. L., a 57-year-old woman from Pueblo, Mexico, was seen at the Johns Hopkins Hospital because of precordial pain, and was examined by one of us. The family history was negative for pigmentation, but intestinal trouble was present in the form of "strangulated hernia" in the maternal grandfather, chronic indigestion in a brother and fatal gastric hemorrhage in the father.

The patient was an obese woman with hypertension and typical angina pectoris. Intestinal complaints were denied. The pigmented spots of the lips and oral mucosa, which were similar to those in our other cases and are shown in Figure 17, had been present for at least 8 years and possibly longer. This point, however, was not too clearly established. The spots were located on the vermilion border of the lower lip, to a less extent of the upper lip, on the buccal mucosa and on the hard palate. There were a few small light spots on the palms and volar aspects of the fingers, but none were seen on the feet. The spots in and around the mouth varied in dimension from pin-point size to about 6 mm. in the largest measurement. They were brown black. On observation under magnification the spots had a definite, stippled appearance similar to that in Case 7, 8, 9 and 10.

Barium enema, including a double contrast air study, was negative, as were an upper gastrointestinal study and sigmoidoscopy. The stools were negative for occult blood. No special small-bowel study was made.

Because of the absence of gastrointestinal symptoms and negative studies, it was concluded that the patient probably did not have intestinal polyposis.

*We are indebted to Dr. R. Carmichael Tilghman for calling this case to our attention and for permission to publish it.

(To be concluded)

References

1. Jeghers, H. Pigmentation of skin. *New Eng. J. Med.* **231**:88-100, 122-136 and 181-189, 1944.
1a. Ravitch, M. M. Polypoid adenomatosis of entire gastrointestinal tract. *Ann. Surg.* **128**:283-298, 1948.
2. Hutchinson, J. Pigmentation of lips and mouth. *Arch. Surg.* (London) **7**:290, 1896.
3. Connor, J. T. Aesculapian Society of London. *Lancet* **2**:1169, 1895.
4. Weber, F. P. Patches of deep pigmentation of oral mucous membrane not connected with Addison's disease. *Quart. J. Med.* **12**: 404-408, 1919.
5. Hopkins, S. J. (London). Personal communication.
6. Weber, F. P. (London). Personal communication.
7. Peutz, J. L. A. Very remarkable case of familial polyposis of mucous membrane of intestinal tract and nasopharynx accompanied by peculiar pigmentations of skin and mucous membrane. *Nederl. maandschr. v. geneesk.* **10**:134-146, 1921.
8. Meirowsky, E. Idiotypische Pigmentanomalien. In *Handbuch der Haut und Geschlechtskrankheiten.* Edited by J. Jadassohn. Vol. 4. Part 2. 1490 pp. Berlin: Julius Springer, 1933. P. 624.
9. Metzger, H., Ohlmann, J., and Halff, M. Un cas de polypose du côlon. *Arch. d. mal. de l'app. digestif* **25**:90-95, 1935.
10. Peutz, J. L. A. (The Hague). Personal communication.
11. Foerster, A. Naevi spili der Mundschleimhaut bei Vorhandensein von Naevi spili der Haut in ausgedehnter, ungewöhnlicher Form. *Dermat. Wchnschr.* **83**:1435-1437, 1926.
12. Siemens, H. W. Zur klinisch-ätiologischen Analyse und Systematik kleinfleckiger Pigmentierungen, nebst Beschreibung einer besonderen Form von Epheliden. *Dermat. Ztschr.* **53**:575-591, 1928.
13. Kisch, B. (New York City). Personal communication.
14. van Dijk, J. A., and Oudendal, A. J. F. Adenoma of small intestine with contribution to knowledge of heredity in tumors. *Nederl. tijdschr. v. geneesk.* **69**:966-973, 1925.
15. Foster, D. B. E. Adenocarcinoma of small intestine in father and daughter. *Brit. M. J.* **2**:78, 1944.
16. *Idem.* (Cardiff, Wales). Personal communication.
17. Touraine, A., and Couder, F. Syndrome de Peutz (Lentigino-polypose digestive). *Ann. de dermat. et syph.* **5**:313, 1945.
18. *Idem.* Lentiginose péri-orificielle et polypose viscerale. *Presse méd.* **54**:405, 1946.
19. Ferrari, A. V. Pigmentazioni buccali a trasmissione ereditaria. *Boll. d. ses. reg. d. Societa italiana di dermat. e sif.* **10**:300-302, 1931.
20. Belote, G. H. Gumma of nose; tuberculosis. *Arch. Dermat. & Syph.* **35**:539, 1937.
21. Cawley, E. P. (Ann Arbor, Michigan). Personal communication.
22. Crouzon, M. M., and Chatelin, C. Un nouveau cas de pigmentation des muqueuses de cause inconnue. *Bull. et. mem. Soc. méd. d. hôp. de Par.* **34**:445-448, 1912.
23. Hudelo, L., and Rabut, R. Pigmentation de la muqueuse buccale. *Bull. Soc. franc. de dermat. et syph.* **34**:198-201, 1927.

HYPERTENSION DUE TO PARTIAL RENOVASCULAR OCCLUSION

Report of a Case

PHILIP M. CORNWELL, M.D.*

HARTFORD, CONNECTICUT

IN 1934 Goldblatt[1] aroused much interest by the publication of the results of his experimental production of hypertension in dogs by ingeniously reducing the blood flow through one or both renal arteries. Other investigators have abundantly confirmed his findings.

Within a short time of the appearance of this paper clinical case reports of hypertension in human beings, apparently caused by similar circumstances, began to appear in the literature. It became apparent that severe hypertension from such causes was a very real, but nonetheless a relatively rare, entity. Large series of cases of hypertension have been subjected to searching urologic study, only a small proportion exhibiting unilateral renal disease of possible etiologic significance. Clinical study of the problem has indicated that arterial hypertension can result from any type of renal disease that produces a marked reduction, but not complete ablation of the blood flow through the kidney.

The case reported below is unusual in that the pathologic process exactly reproduced the conditions of Goldblatt's experiments and that it was possible to follow the clinical course of the disease almost from the onset of the vascular obstruction.

CASE REPORT

M. P. was a 35-year-old factory worker. Her past medical history included an osteomyelitis of the left tibia at the age of 14 that had required several surgical procedures before final healing had been attained; this condition had caused no trouble for 20 years. In 1942 she had suffered a bilateral uveitis, which had responded satisfactorily to the removal of several infected teeth and fever induced by intravenous injection of typhoid vaccine. At that time a careful examination of the retinas by a competent ophthalmologist was recorded as showing no retinal abnormalities. The blood pressure was noted to be 132/88. From 1942 until the onset of the illness under discussion she had been entirely well except for several minor ailments for which she consulted her family physician. On three of these occasions he had recorded her blood pressure at 130/80.

On November 4, 1947, at 7 a.m., she experienced a sudden severe, cramping pain in the right upper abdomen. Within the next few hours the pain became dull and moved to the midportion of the abdomen lateral to the umbilicus on the right side. She became nauseated and vomited twice. By mid-afternoon she became so uncomfortable that she was forced to leave work and go home. By this time the pain centered in the right costovertebral angle and the right flank, where it remained the rest of the day and all that night. She ate no supper, vomited bile several times during the night and was unable to sleep. On the following morning she called her doctor, who advised hospitalization for study with a tentative diagnosis of acute retrocecal appendicitis.

On admission to the hospital she still had some pain but it was much less severe and entirely in the right costovertebral angle. She appeared somewhat pale, but otherwise seemed healthy. The head and neck were unremarkable. A few crackling rales were audible at the base of the right lung posteriorly. The heart was of normal size, the rhythm was regular, and no murmurs were heard. There was slight resistance to palpation in the right upper quadrant of the abdomen, and slight tenderness was elicited in the right costovertebral angle. Rectal examination was negative. The introitus was virginal. The extremities were normal, and the deep and superficial reflexes were physiologic.

The temperature was 100°F. by mouth, the pulse 60, and the respirations 18. The blood pressure was 110/70.

Examination of the blood showed a white-cell count of 12,850, with 91 per cent neutrophils. The hematocrit was 40 per cent. The urine was acid, had a specific gravity of 1.015 and gave a + test for albumin but contained no sugar; only rare white blood cells were noted in the sediment.

After admission all the symptoms rapidly disappeared. The elevated white-cell count, with a marked shift to the left, tended toward normal. Except for the initial temperature of 100°F. the patient remained afebrile. On the 3rd hospital day an intravenous pyelogram showed a normal left upper urinary tract, but no excretion of the Diodrast was noted on the right side in any of the films.

On the 5th day after admission cystoscopy and retrograde pyelography were done. The bladder and urethra were normal. Both ureteral orifices were in their normal location and appeared normal. Urine was seen to emerge from the left orifice in normal peristaltic spurts, but none was seen to issue from the right side. Catheters were passed easily to each kidney pelvis. Indigo carmine injected intravenously appeared promptly in strong concentration from the left side, but there was no drainage whatever from the right catheter although irrigation with sterile water was easily accomplished with no evidence of obstruction of the catheter. Films were made before and after the catheters had been injected with an opaque medium. No calcific shadows were visible in the renal, ureteral or bladder areas. The tips of both catheters were apparently well placed in the renal pelves. The renal parenchymal shadows on each side were equal and normal. The kidney pelves, calyxes and ureters were well filled with contrast material and appeared entirely normal.

On the strength of these findings it was believed that the patient had suffered an obstruction to blood flow through the right kidney of undetermined cause. The blood pressure was rechecked on the following day and found to be 160/90 in contrast to the 110/70 recorded on admission to the hospital a week before. Thereafter, daily blood-pressure readings were taken — all by the same observer and all at approximately the same time of day. A steady rise of both systolic and diastolic readings was noted until, on the 13th day after the onset of the illness, a blood pressure of 180/110 was recorded. On the preceding day the patient had complained of throbbing headache and blurring of vision. An ophthalmologist noted moderate straightening and narrowing of the retinal arterioles and early arteriovenous nicking.

At this time the basal metabolic rate was + 6 per cent, and the blood cholesterol 258 mg. and the nonprotein nitrogen 27 mg. per 100 cc.; the blood sedimentation rate was 13 mm. in 1 hour, and the white-cell count was 11,300, with 82 per cent neutrophils; the phenolsulfonephthalein test showed 45 per cent excretion of the dye in 1 hour. The prothrombin time was 100 per cent of normal, and a chest x-ray examination was negative.

The right ureter had been catheterized a second time 3 days after the first cystoscopic examination, and the original findings confirmed. On the 14th day after the onset of the illness the right kidney was exposed through a flank incision. The organ appeared pale and a little bluer than usual. It

*Assistant urologist, Hartford Hospital.

was readily mobilized, and the vascular pedicle carefully isolated. The renal artery was small, and no pulsations could be seen or felt. It was followed toward its origin until it disappeared beneath the vena cava without the demonstration of any pulsating portion. At the hilus of the kidney the artery divided into two main branches. One of these divisions was deliberately cut without clamping, and a thin trickle of blood, with no pulsatile quality whatever to the flow, emerged. The artery was then clamped, cut and ligated, and the veins similarly treated. The ureter was divided between ligatures, and the kidney removed. The flank wound was closed in layers with drainage.

Postoperatively the blood pressure was carefully followed, and during the 9 days in the hospital after operation the systolic pressure varied from 100 to 120 and the diastolic from 60 to 80. Two weeks after discharge the blood pressure was 116/77, and on 9 subsequent occasions up to 17 months postoperatively has never been higher than 120/80 or lower than 110/70. The patient has remained well and vigorously active.

The kidney was subjected to careful pathological examination, and the following is the description of the organ by the pathologist*:

> The specimen consists of a right kidney measuring 12 by 5 by 4 cm. The capsule is rather densely adherent to the cortex. On gross section an essentially normal medullary architecture is seen. The entire parenchyma is intensely engorged and deep purple in color. The pelvic mucosa is grossly normal. The extrarenal arteries are patent. In some areas portions of the medullary rays are outlined by interstitial hemorrhage.
>
> Microscopical sections of the kidney have a most striking histologic appearance. The pyramidal portions show extensive necrosis, with hemorrhage extending throughout these zones. There is little evidence of inflammatory exudate surrounding these areas of necrosis. The vessels at the margins are intensely congested. In contrast, the cortex appears intact except in one section, where a small, fresh infarct is seen. The cortex shows intact glomeruli whose capillaries are engorged. The juxtaglomerular apparatus, particularly the macula densa, is unusually prominent in many glomeruli. The convoluted tubules appear small and collapsed, and the epithelial lining is atrophic, resembling that seen in the collecting tubules. Frequently, the epithelial cells have a pale, vacuolated cytoplasm. The blood vessels throughout are thin walled. No evidence of local vascular occlusion is seen in the many sections studied.
>
> The histologic changes are those of profound ischemia, with infarct-like zones limited almost exclusively to the medulla. The generalized atrophy of the convoluted tubules is undoubtedly secondary to renal ischemia. The apparent prominence of the juxtaglomerular apparatus may be accentuated by the atrophy of the surrounding tubular epithelium, which brings out the macula densa especially clearly.

Discussion

As is evident from the foregoing report, accurate knowledge of the cause of the proved partial obstruction of the right renal artery is lacking. It is probably justifiable to attribute it to an atheromatous plaque in the aorta at the origin of the renal artery or in the proximal portion of the renal artery itself.

It was evident that vascular occlusion was present when an anatomically normal kidney with complete loss of function was demonstrated. It was surmised that the obstruction must be incomplete when the blood pressure was found to be rising rather abruptly.

It is interesting to speculate on what would have occurred had the kidney not been removed. The appearance of headache, blurred vision and retinal changes associated with rapidly increasing arterial pressure led me to believe that the entire picture of malignant hypertension would have developed and would have become irreversible as soon as the peripheral arterioles began to show degenerative changes. This belief is strengthened by the experimental observations of Goldblatt[1] and more recently of Selye,[2] of Montreal. Whether the renal cells responsible for the hypertension are in the juxtaglomerular apparatus, as Goormaghtigh[3] contends, or in the descending loop of Henle, as Selye[2] believes, is of no importance in this case, since both areas were uninvolved in the necrosis present in the kidney.

A point of some interest for which I do not have an explanation is the appearance of necrosis in the medullary portion of the kidney whereas the cortex remained uninvolved. If the disputed "shunting" vessels of Trueta[4] actually exist, one would expect the greater damage to be seen in the cortex.

Summary

A case of hypertension due to partial occlusion of the right renal artery, with cure of the hypertension by nephrectomy, is presented. The case is of unusual interest because it was possible to observe the entire development of the hypertensive syndrome and correlate it with the clinical symptoms produced by the arterial occlusion. A follow-up period of eighteen months revealed no tendency to a recurrence of the hypertension.

85 Jefferson Street

*Reported through the courtesy of Dr. Robert Tennant, Department of Pathology, Hartford Hospital.

References

1. Goldblatt, H., Lynch, J., Hanzal, R. F., and Summerville, W. W. Studies in experimental hypertension. I. Production of persistent elevation of systolic blood pressure by means of renal ischemia. *J. Exper. Med.* 59:347-380, 1934.
2. Selye, H. Unpublished data.
3. Goormaghtigh, N. Histological changes in ischemic kidney, with special reference to juxtaglomerular apparatus. *Am. J. Path.* 16: 409-416, 1940.
4. Trueta, J., et al. *Studies of the Renal Circulation.* 187 pp. Springfield, Illinois: Charles C Thomas, 1947.

PULMONARY EFFECTS OF THE COCOANUT GROVE FIRE

A Five-Year Follow-Up Study

HELEN S. PITTMAN, M.D.,* AND RICHARD SCHATZKI, M.D.†

BOSTON

THE Cocoanut Grove fire took place on November 28, 1942. In a previous report[1] we described the initial pulmonary complications in the group of 39 patients admitted to the Massachusetts General Hospital. Finland[2] has already published the follow-up findings in his series of 92 patients discharged from the Boston City Hospital. He found that symptoms of respiratory disease at four, nine and twenty-six months after the fire were neither frequent nor severe. Persistent cough was the most common symptom at each time period. An occasional patient later began to raise copious amounts of mucopurulent sputum (12 of the 38 patients reporting at twenty-six months). This he regarded as suggesting the development of bronchiectasis.

This study concerns the status of the Massachusetts General Hospital patients five or more years after the fire. The interval seemed sufficient to have permitted the development of any late pulmonary complications that were going to occur.

PLAN OF STUDY

We have written to 29 of the 32 patients discharged from the Massachusetts General Hospital. The other 3 were service men who remained in the hospital only until transfer to Army or Navy installations was arranged. We had no permanent addresses for these 3 patients. We know that 2 of them were returned to full duty by December 12, 1942.

The study was based on questionnaire, physical examination, vital-capacity estimation and roentgenographic examination.

RESULTS OF STUDY

Sixteen patients returned for examination, 6 reports were received by mail, and 7 persons could not be traced. Three of the 6 mailed reports included completed questionnaires (Case 9, 10 and 14). Two patients had died (Case 15 and 20). One is apparently psychotic (Case 35).

Of the 3 patients from whom we have current information but whom we have not seen, 1 is well and 2 have slight dyspnea on exertion. Answers to their questionnaires are indicated in Table 1.

CASE 9. The patient has occasional dyspnea on effort and raises fairly large quantities of thick mucus in the mornings. This case was classified as Grade I severity of lung complications, and the patient was discharged a few hours after the fire without having chest x-ray films taken.

CASE 10. The patient, a physician, reports himself as well except for occasional asthma, which he had before the fire.

CASE 14. The patient reports that he has some shortness of breath on walking uphill and that he has some wheeze. He has no other symptoms referable to the respiratory tract.

TABLE 1. *Replies to Questionnaire (10 Cases).*

Question No.	Question	Yes	No
1	Have you any chronic cough?		16+3*
2	Are you short of breath?	2*	16+1*
	If so, do you notice it at rest?		16+3*
	Do you notice it when walking on the level?		16+3*
	Do you notice it when walking uphill?	2*	16+1*
3	Have you any wheeze?	1*	16+2*
4	Are you hoarse?		16+3*
5	Do you raise any sputum?	1+2*	15+1*
6	Do you ever spit blood?		16+3*
7	Do you have pain in your chest?		16+3*
8	Do you have discharge from your nose?	2	14+3*
9	Do you have a chronically sore throat?	1	15+3*

*Replies so designated refer to patients answering by mail and not interviewed.

Immediately after the fire he had a transient inspiratory wheeze over the front of the left side of the chest and in the left axilla. There was never any abnormal finding in his x-ray film, and examination of his chest was negative at the time of discharge from the hospital on December 10.

CASE 15. This patient committed suicide on January 9, 1943, by jumping through a window.

CASE 20. This patient died on February 3, 1945. In December, 1943, she was operated on for an adenocarcinoma (Grade III) of the left breast, with axillary metastases, in the Baker Memorial Hospital. X-ray films of the lungs were clear at that time.

CASE 35. The patient is reported as being a "psychologic case." She "will not permit a doctor to see her."

PHYSICAL EXAMINATION

Of the 16 patients who have been examined 15 are clinically well so far as their lungs are concerned. One patient (Case 16), a man now sixty-three years old, is symptom free; on examination there were persistent rales in the right axilla.

The results of vital-capacity determination are shown in Table 2.

ROENTGENOLOGICAL FINDINGS‡

Sixteen of the original group of survivors had roentgenologic examinations for this follow-up study, varying from five to six years after the catas-

*Instructor in medicine, Harvard Medical School; associate physician, Massachusetts General Hospital.

†Instructor in radiology, Harvard Medical School; radiologist, Mount Auburn Hospital, Cambridge; assistant radiologist, Massachusetts General Hospital.

‡We are indebted to Dr. Stanley Wyman, of the Massachusetts General Hospital, for the performance of a number of the roentgenologic examinations.

trophe. Two of these (Case 21 and 31) had not had any roentgenologic studies at the time of the fire.

Films during inspiration and expiration, as well as lateral films, were obtained. Fluoroscopy was performed whenever it was thought to be indicated. The observation concentrated on the presence or absence of scars, areas of atelectasis, emphysema and the position of the diaphragm in inspiration and expiration.

TABLE 2. *Vital-Capacity Data.*

CASE No.	SEX	VITAL CAPACITY*		
		FIRST DETERMINATION	PRESENT DETERMINATION	
		%	%	liters
1	M	108	117	5.2
2	F	48	91	3.8
4	F	83	89	2.9
6	F	25	98	3.2
11	M	Not determined	Not determined	
13	F	29	82	2.9
16	M	51	83	3.8
21	F	Not determined	105	3.2
23	F	Not determined	93	3.0
26	M	56	120	5.2
30	F	Not determined	85	2.7
31	M	Not determined	88	3.8
32	F	Not determined (Tracheotomy)	111	3.6
36	M	58	114	5.3
37	M	44	113	4.6
39	F	84	84	2.6

*Percentages of values theoretically regarded as normal.

Of the 16 cases, 13 showed no variations from normal in any respect. Two of the remaining cases (Case 4 and 13) showed each a single vertical line in the lower-lung field, representing either a linear scar or a very thin area of plate-like atelectasis. One patient (Case 4) had had seven roentgenologic examinations between the second day and the seventh week of the fire; none of the examinations had shown any abnormality. It is unlikely that the present minimal variation from normal is connected with the disaster. Clinically, the patient is perfectly well. The patient in Case 13, in contrast, had had evidence of atelectasis when seen seventeen weeks after the fire. A third case (Case 21) showed a few similar lines in a basal segment of the right lower lobe. This patient had had no roentgenologic examination at the time of the fire. She had had a virus pneumonia in the spring of 1943. She showed at the time of examination no clinical evidence of disease. The only residual abnormal findings, then, that might conceivably be attributed to the disaster are the minimal areas of scarring or atelectasis present in Case 13 and 21. Both patients are symptom free.

At the end of the original observation period six years ago, only 2 cases showed residual roentgenologic changes (Case 13 and 19). Case 13 still shows a linear scar or area of atelectasis. We were not able to trace the patient in Case 19, who, when last seen eighteen weeks after the fire, still had evidence of air trapping.

DISCUSSION

Analysis of Abnormal or Questionable Findings

Two patients (Case 9, a twenty-seven-year-old woman, and Case 14, a thirty-four-year-old man) report occasional dyspnea on effort. The former raises fairly large quantities of thick mucus in the morning, and the latter also raises mucus at the same time. A twenty-nine-year-old man (Case 11) raises a little white or yellow sputum in the morning; he smokes about a package of cigarettes a day. These two complaints are not uncommon in unselected groups of the general population in this climate. The one person (Case 21, a thirty-one-year-old woman) who reports a chronically sore throat dates it from her second delivery in 1946. This is the patient discussed under the section on roentgenology who had a virus pneumonia in 1943.

Vital-capacity estimations show variations from 85 to 117 per cent of the theoretical normal. By this method (McKesson and Scott) 85 per cent of theoretical normal is considered within normal limits; 3 of our patients fell just below the accepted normal level.

Status of Cases Described in Detail in First Report

In our original report we described certain case records as illustrating the characteristics of the different degrees of severity of lung complications.

CASE 36 was used to illustrate Group 2 (rales and emphysema). This man later served overseas as a war correspondent. He is clinically well. His vital capacity, which was 58 per cent of theoretical normal soon after the fire, is now 114 per cent.

CASE 6 was used to illustrate Group 3 of lung complications (rales, emphysema and persistent atelectasis attributed to edema of the air passage). She is now 20, a student in college. She is clinically well. Her vital capacity, which was initially reduced to 25 per cent, is now 98 per cent of theoretical normal.

CASE 20, which we described to illustrate Group 4, has since died, presumably from carcinoma of the breast. Unfortunately, she died outside the hospital so that there was no opportunity to examine the lungs anatomically.

CASE 13. This patient is now clinically well so far as her lungs are concerned and is about to be married. She has some degree of nasal obstruction after plastic operations to her burned nose. Her initial vital capacity was 29 per cent; it is now 82 per cent.

CONCLUSION

From the data on the 16 patients whom we have recently examined clinically and roentgenologically and the 3 additional patients reporting by mail, persistent cough is not reported by any patient and only 3 of the 19 raise any sputum. It seems probable that there is no persisting or secondary pulmonary disease resulting from the fire damage.

REFERENCES

1. Cope, O., et al. Management of Cocoanut Grove burns at Massachusetts General Hospital. *Ann. Surg.* 117:801-965, 1943.
2. Finland, M., Davidson, C. S., and Levenson, S. M. Clinical and therapeutic aspects of conflagration injuries to respiratory tract sustained by victims of Cocoanut Grove disaster. *Medicine* 25: 215-283, 1946.

ODDITY OF PREGNANCY

LOUIS LEVINE, M.D.,* AND ROBERT H. GOODWIN, M.D.†

NEW BEDFORD, MASSACHUSETTS

CURIOUS alterations of appetite of the most bizarre nature occur in some pregnant women.

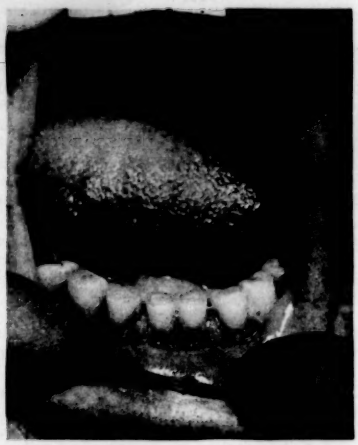

FIGURE 1. *Photograph of the Patient's Teeth, Showing the Abraded Lower Central Incisors.*

The following case concerns a pregnant woman with an insatiable desire to eat coal.

*Member of courtesy staff, St. Luke's Hospital; member of associate staff, Acushnet Hospital.

†Obstetrician-in-chief, St. Luke's Hospital.

CASE REPORT

A well developed and well nourished 39-year-old woman came to the office in her 37th week of pregnancy. She had had eight normal pregnancies, and 7 of the children were living and well. The heart and lungs were essentially normal. The blood pressure was 120/80. There was a vertex presentation, in the left occipitoanterior position, and the fetal heart tones were normal. The teeth were in poor condition, gray and completely eroded or abrased (Fig. 1). These flat, table-shaped teeth led to further questioning, which brought to light her strange diet. When she was about 16 weeks pregnant, she suddenly experienced an urge to eat coal. Since her home was heated with oil, she made her husband purchase a 100-pound bag of pea coal. She chewed and ate two or three pieces of coal daily, carefully washing it with water before eating it. She continued to indulge in this strange diet, chewing the coal until the 37th week, when her teeth became eroded and soft and when she began to break up the lumps into small pieces before eating.

She was never constipated and stated that she saw the small pieces of coal in her feces after each bowel movement. She took a normal diet otherwise, and had had no desire to eat coal or any other special foods during her previous pregnancies. She had had no medical or prenatal care previous to being seen by one of us (L. L.) during the 37th week of pregnancy.

She was given dicalcium phosphate with vitamin D, 2 tablets four times daily, and told to refrain from continuing her coal diet. The calcium seemed to satisfy her, and she stopped eating coal. Three weeks later she delivered a normal female infant in the hospital. She had an uneventful puerperium, and now requires extensive dental care.

SUMMARY

A case of a craving for coal, which developed during pregnancy, is presented. This craving was relieved by a prescription of dicalcium phosphate. Permanent damage to the teeth resulted from the coal diet. So far as is known, no similar cases have been reported.

MEDICAL PROGRESS

VITAMIN SUPPLEMENTATION IN HEALTH AND DISEASE (Continued)*

PERRY J. CULVER, M.D.†

BOSTON

NUTRITIONAL SURVEYS AND SUBCLINICAL VITAMIN DEFICIENCY

With the exception of one report,[68] nutritionists in general note that frank deficiency diseases, especially vitamin-deficiency diseases, have almost disappeared during the last decade in the United States.[12, 72-74] The majority of cases of clinical vitamin deficiency now seen are in association with chronic alcoholism or some debilitating disease,[72] and a moderate number of cases of scurvy occur in infants because mothers boil the orange juice or cater to dietary dislikes.[75] The cause of this reduced incidence of gross vitamin deficiency in the United States is unexplained. Blankenhorn[72] observes that deficiency began to disappear before the enrichment of flour was practiced generally and has continued to wane in spite of the high cost of food, indicating that improvement is probably not due to gain in economic status.

On the other hand, a survey of the many studies of the nutritional state of prisoners of war and of the populations of occupied countries during World War II showed that vitamin deficiency becomes prevalent under adverse conditions. Only a few of these reports are reviewed here. Cartwright and Wintrobe[76] elicited a history of pellagra in 50 to 70 per cent, wet beriberi in 77 per cent and dry beriberi in 50 per cent of war prisoners from the Philippines and from Japan. Similar findings in the Pacific Theater were reported by others.[77, 78] In general, the deficiencies were multiple, but two other outstanding symptoms attributed to inadequacy of components of the vitamin B complex were the "burning-feet" syndrome and retrobulbar neuritis.[24, 49, 79-82] The syndrome of "burning feet" at night was observed previously in the Spanish Civil War.[83] The important information about these two newer syndromes of vitamin deficiency is their failure to respond to crystalline thiamine or nicotinic acid supplements alone, but they improve after ingestion of brewers' yeast or a luxurious diet.[24, 49, 80, 82] It was mentioned above that the "burning-feet" syndrome might be due to pantothenic acid deficiency.[49]

In contrast with these reports from the Pacific area, the results of nutritional surveys among European civilians and prisoners of war showed a minimum of vitamin-deficiency signs, although they were very much undernourished with respect to calories.[84-87] The difference between the European and Pacific types of starvation is probably due to the fact that the diet in the Pacific Theater was primarily carbohydrate, secondary diseases such as dysentery adding to the burden of maintaining adequate vitamin intake. In Europe, however, the dietary intake was generally restricted but more nearly balanced with almost adequate protein and borderline vitamin intake. It should be noted that the vitamin requirements were somewhat reduced by the decrease in metabolic rate that occurs in semistarvation.[85, 87]

To return to the problem of vitamin deficiency in the United States, in addition to the reports of the rarity of clinical vitamin deficiency today, the proponents of widespread avitaminosis have been dealt a further blow through recent critical surveys, which have demonstrated that many of the so-called specific signs of vitamin deficiency are not caused by a lack of vitamins but by other factors, which are often nonnutritional. The thickening of bulbar conjunctivas, which was formerly attributed to vitamin A deficiency, remained unchanged after two years of therapy with 50,000 I.U. of vitamin A per day.[13] Similar, but not quite as definitely negative, results of therapy were obtained by Borsook et al.[88] Darby and Milam[74] found no correlation between the skin lesions supposedly caused by vitamin A deficiency and low plasma vitamin A levels or a low daily intake of vitamin A. Others have stated that keratosis pilaris is more often due to a deficiency of soap and water than to a lack of vitamin A.[89, 90] These facts are strong evidence that the so-called signs of vitamin A deficiency are not specific.

Abnormal reflexes, calf-muscle tenderness, plantar dysesthesia and loss of vibratory sense have been considered specific signs of inadequate thiamine intake. Borsook et al.[88] failed to observe any therapeutic effect of large doses of thiamine, administered over a long period to a group of young aircraft workers, some of whom manifested these symptoms. Likewise, Darby and Milam[74] found no relation between a low level of thiamine intake and abnormalities of vibration sense, which were found in adults only. These observations suggest both that the specificity of such symptoms of athi-

*From the Medical Clinics, Massachusetts General Hospital, and the Department of Medicine, Harvard Medical School.

†Associate in medicine, Harvard Medical School; assistant in medicine, Massachusetts General Hospital.

aminosis is untrue and that the concept of thiamine-deficiency incidence based upon these signs should be revised downward.

The signs most often associated with riboflavin deficiency — namely, corneal vascularization, angular fissures and changes in the buccal mucosa and tongue — have been found without relation to a low intake of riboflavin.[74, 91] The corneal vascularization may just as often be associated with physical trauma such as sun, wind or dust,[92] whereas Darby[93] states that at the Vanderbilt Hospital Nutrition Clinic stomatitis due to iron deficiency is seen more frequently than cheilosis and glossitis caused by lack of riboflavin or niacin.

Another example of nonspecificity of a supposedly characteristic sign of vitamin inadequacy — in this case, vitamin C — is gingivitis or swelling and blueness of the gums. There are several reports of gingivitis in 50 per cent or more of adults examined, but the gingivitis is associated with poor oral hygiene rather than with low plasma ascorbic acid levels[74] and does not decrease after administration of 100 to 200 mg. of vitamin C for three months or longer.[94, 95] Although oral hygiene plays a major role in prevention of gingivitis, vitamin C may contribute, as shown in a well controlled study by Linghorne et al.[96] They found that ascorbic acid therapy alone would not improve gingivitis but that, once local therapy had alleviated involvement of the gums, daily intakes of more than 22 mg. of vitamin C would deter the recurrence of gingivitis.

Inasmuch as many estimates of the incidence of vitamin deficiency in the United States have been based upon the presence of signs that are now shown to be nonspecific, I believe that the problem of vitamin deficiency is minimal. Therefore, it becomes apparent that, with few exceptions, food intake supplies the minimal requirement of essential vitamins, and the widespread use of vitamin supplements does not seem indicated for treatment of an almost nonexistent vitamin-deficiency state.

There still remains the possibility that vitamins in addition to those in the general diet are of value for improving health or well-being and for promoting recovery from disease. Information obtained from review of the following studies of this problem will indicate whether or not the average American diet contains optimal quantities of vitamins.

To quote from Keys,[97] who appreciated the necessity of restricting his interpretation to the small number of studies on vitamin-fitness relations that were acceptable and well controlled, "the great bulk of the evidence indicates no gain in fitness of adults from vitamin supplementation added to a good American diet." There is no improvement in tolerance to hot or cold environments from the use of vitamin supplements and no good evidence that vitamin requirements are increased during extremes of temperature.[98, 99] Contrary to the statement that "biochemical avitaminosis" has been found to exist in the majority of aged persons,[100] Vernon and McKinlay[101] found no beneficial effect, over a twelve-month period from vitamin supplementation in senile patients. In two well controlled studies involving more than 500 employees of an aircraft plant[91] and 241 steel workers,[102] daily supplements of a multivitamin capsule showed no more beneficial effect on sense of well-being, absenteeism, appetite, sleep and increased output of work than did placebo capsules. Comparison with a control group receiving neither placebos nor vitamin capsules leaves no doubt about the psychologic and morale-improving effect of any sort of medication. It is the psychologic effect of vitamin supplements that opens to question the many reports of beneficial effects. It has already been mentioned that added vitamins failed to alter the biomicroscopic lesions observed among the aircraft workers.[91] These two reports have an increased value in an attempt to determine whether there is need for supplementing the average American diet with vitamins because dietary surveys among these workers showed that intakes of vitamins were below the recommended dietary allowances of the National Research Council in a large number of the subjects.[88] As additional evidence, it was found that vitamin supplements had no effect on the growth, strength, nutrition, fatigue potential, incidence or severity of clinical conditions, hearing and absenteeism among 1620 British schoolchildren observed over a one-year period of controlled study.[103] Dietary surveys made in conjunction with this investigation showed that the average vitamin intakes were well below recommended standards and cast doubt upon the validity of the American "recommended dietary allowances."[108]

In another three-year study of 315 workers in trinitrotoluene, multivitamin capsules did not decrease the occurrence of toxic symptoms in the treated group as compared with controls.[104] In this study there was an interesting but probably not significant observation of 14 cases of hepatitis among the treated group in contrast to only 2 cases among the controls.

In addition to these reports of the general ineffectiveness of vitamin supplements, several investigations show lack of benefit from the administration of specific vitamins in certain pathologic states. These findings undermine opinion widely accepted previously that the specific vitamins were indicated in these conditions; 50,000 to 150,000 I.U. of vitamin A per day did not decrease color blindness[104] or reduce thickening of the bulbar conjunctivas.[13, 91] Diabetic neuropathy is not relieved by large doses of thiamine and other components of the vitamin B complex, but only by adequate insulin and diet therapy.[105-107] Moreover, diabetic neuropathy has developed in patients who

have been taking excessively large doses of vitamins.[106] There was no evidence that large doses of crystalline components of the vitamin B complex had any significant effect upon rate of healing or survival after severe burns.[36] A study of the effectiveness of various types of therapy in hepatic cirrhosis by means of serial liver biopsies raises doubt whether supplements of vitamin B complex have any beneficial effect beyond that of a high-carbohydrate, high-protein diet alone,[108] and excess quantities of vitamins had no protective effect on liver function as measured by urobilinogen excretion and bromsulfalein clearance during postoperative convalescence.[109] Although one investigation showed a slight beneficial effect of added thiamine over placebo tablets in the mental responses of children in an orphanage as measured by results of 15 out of 30 aptitude tests,[110] the results are probably not significant. Moreover, negative results for improvement in growth, vision and learning after administration of 2-mg. supplements of thiamine to 1 of each of 25 pairs of identical twins for nine months were observed in a carefully planned study by Robertson et al.[111] These negative findings are even more impressive when it is noted that 50 per cent of the experimental subjects were eating 20 to 40 per cent less vitamins than the optimal levels of the "Recommended Dietary Allowances."

The conclusion to be drawn from these investigations is that the American diet, even though it may contain a smaller quantity of vitamins than the generous recommendations of the National Research Council suggest, generally supplies optimal amounts of vitamins and that the indiscriminate use of vitamin supplements does not benefit public health or promote recovery from diseases. Such a conclusion does not deny the existence of an occasional case of vitamin deficiency that requires short-term vitamin supplementation, nor does it deny that the use of large doses of specific vitamins may not be of benefit in certain diseases in which the vitamin has a pharmacologic rather than a nutritive action. Reports of the specific therapeutic uses of vitamins are reviewed below.

Specific Therapeutic Uses of Vitamins

Reports of the curative or beneficial effect of large doses of a specific vitamin in a given disease are legion, and such reports, along with advertisement of supposed malnutrition, have acted as stimulants to vitamin sales. In many cases reports of therapeutic success with a vitamin are the result of uncontrolled clinical investigations that do not consider either the natural history of the disease or the possible psychologic effect of vitamin pills. At the risk of omitting many valuable references, only a few investigations can be reviewed.

Massive doses of vitamin A have been a therapeutic favorite of dermatologists; 100,000 to 240,000 I.U. of vitamin A are said to bring about slow improvement in some cases of Darier's disease.[112,113] Similar doses of vitamin A were believed to cause regression in both seborrheic and senile keratoses in all 50 cases treated for three or four months, whereas 30 control cases remained unchanged.[114] Thirty-seven per cent of 42 cases of plantar warts were cured by 100,000 I.U. of vitamin A daily for five weeks to nine months.[115] Although the results with vitamin A were not nearly as effective as x-ray therapy, the investigators recommend vitamin A treatment because of its safety. Massive doses of vitamin A also are reported to improve pityriasis rubra pilaris.[116] A striking clinical and pathological improvement was shown by 14 of 18 cases of leukoplakia vulvae treated with 250,000 to 500,000 units of vitamin A per day by mouth, in addition to 50,000 units twice a week by injection.[117] If confirmed, this observation has considerable significance in view of the difficulties associated with the treatment of leukoplakia vulvae.

I agree with many conservative dermatologists who are skeptical about reports of therapeutic benefits from vitamin A. Consequently, negative reports from well controlled investigations are important for keeping therapeutic enthusiasm in balance. Such a report is that of Lynch and Cook,[118] who found that vitamin A had no special beneficial effects in the treatment of acne vulgaris.

In 2 cases reported by Simkins,[119] "cures" of thyrotoxicosis were effected by the administration of 200,000 to 400,000 I.U. of vitamin A per day for a year. Most clinicians have discounted earlier reports of the effectiveness of vitamin A therapy in hyperthyroidism, but there has been enough suggestive evidence that vitamin A may depress thyroid function to warrant a complete investigation of this problem.

The intravenous use of large doses of crystalline components of the vitamin B complex as an agent for determining arm to tongue circulation time has been reported by Swenson.[120] Although it is not exactly a pharmacologic use of B vitamins, the safety of this method merits consideration. Massive doses of thiamine to decrease the possibility of arsenic toxicity are suggested by Sexton and Gowdey,[121] but as yet this use for thiamine has not had much of a clinical trial. Mention is made of the beneficial effect of very large doses of nicotinamide for all pruriginous states,[122] and of 25 to 300 mg. of nicotinic acid for chilblains.[123]

There has been considerable enthusiasm for the use of pyridoxine in the treatment of radiation sickness during the last five years. Representative reports[124, 125] stress the good results in 60 to 65 per cent of cases treated with oral or intravenous doses of 100 to 400 mg. per day. In view of the constantly changing fashions in the treatment of radiation sickness and of the favorable effects formerly attributed to the use of other components of the vitamin B complex, I believe that there should be

some reservation in accepting pyridoxine as the specific for radiation sickness.

Lewy and Fox[126] report success in the treatment of cases of resistant Ménière's syndrome and of vertigo of undetermined origin with 100 mg. of pyridoxine per day. Intravenous injections of 200 mg. were said to have a remarkable effect on raising the white-cell counts of patients who had been made agranulocytic by thiouracil,[127] but pyridoxine was ineffective in the granulocytopenia of chronic benzene poisoning.[128] The possibility of spontaneous remissions must be considered when the effect of pyridoxine on the granulocytopenia due to thiouracil is evaluated. Other negative reports of value are the failure of pyridoxine in the treatment of epilepsy[129] and in the treatment of nausea and vomiting of pregnancy.[130]

Promise of benefit from the use of daily doses of 400 mg. of calcium pantothenate in 14 cases of discoid lupus erythematosus is reported by Goldman,[131] who is aware of the capriciousness of response of this disease to therapy.

To judge from numerous reports of success, para-aminobenzoic acid seems well established as a specific therapeutic agent in the rickettsial diseases. Flinn et al.[132] compared 10 patients with Rocky Mountain spotted fever who received para-aminobenzoic acid with 13 untreated patients who recovered from the disease. As a result of the drug, the average duration of fever was reduced from seventeen and a half days to ten and a half days, and the treated patients made a more rapid clinical recovery.[132] Ravenel[133] recommended dosages of 0.5 to 1.0 gm. per pound of body weight per day. Because the kidneys excrete para-aminobenzoic acid rapidly, oral administration every two hours is necessary to maintain therapeutic blood levels of 30 to 60 mg. per 100 cc.[132] The drug is buffered in 10 cc. of chilled 5 per cent sodium bicarbonate solution to decrease nausea and acidosis.[133] Administration should be continued for several days after the patient has become afebrile.[133] Greeley[134] suggests using pressed tablets of the sodium salt of para-aminobenzoic acid for slower absorption. If parenteral therapy is necessary, a 25 per cent solution of the sodium salt adjusted to pH 7 may be given by continuous intramuscular or intravenous drip.[134] Since the drug does not kill rickettsias but inhibits their growth, it is most effective early in the disease.[135] Para-aminobenzoic acid has also been effective in scrub typhus[136] and murine typhus.[137]

Further therapeutic possibilities of para-aminobenzoic acid have been enthusiastically but critically described by Zarafonetis.[138] On the assumption that large doses of the drug might inhibit neoplastic cells with disordered metabolic function, daily doses of 48 gm. of the drug were given to patients with leukemia.[138] A marked drop in white-cell count took place, but there was no essential change in the clinical condition of the patients.[138, 139] There is not sufficient space to discuss the rationale for therapy in each type of disease but para-aminobenzoic acid in doses of 15 to 24 gm. per day was found to be beneficial in lymphoblastoma cutis, lupus erythematosus, dermatomyositis, scleroderma and sulfonamide-resistant dermatitis herpetiformis.[138]

Another effect of para-aminobenzoic acid that may be of value clinically is its power to cause a great increase in the blood salicylate level when both drugs are given together.[140] The mechanism of this effect has been shown to be reduced detoxication and decreased urinary excretion of salicylates.[141] Para-aminobenzoic acid may also reduce the metabolic rate of the body. In an unconfirmed report, Berman[142] stated that daily intravenous doses of 1.0 to 1.5 gm. of the sodium salt of para-aminobenzoic acid for three to nine months resulted in a permanent fall of the basal metabolic rate and clinical improvement in all 6 cases of thyrotoxicosis in which this therapy was used.

Several pharmacologic uses for vitamin C have been mentioned, but none of these have confirmation or stem from well controlled studies. Most promising of the group is the report that vitamin C in doses of 500 to 1000 mg. per day caused a great reduction of methemoglobinemia in 2 cases.[143] Chapman and Shaffer[144] found that 250 mg. of ascorbic acid increased the minimum lethal dose of Mercuhydrin for dogs by 50 per cent and suggest that 500 mg. of vitamin C be mixed with 2 cc. of Mercuhydrin in the treatment of congestive failure. Although Klasson[145] reports that 150 to 600 mg. of vitamin C per day seemed to decrease the severity of poison-oak dermatitis and prevented the development of dermatitis in 23 out of 24 poison-oak-sensitive persons after exposure, most dermatologists have been disappointed with the use of ascorbic acid in the therapy of poison-ivy dermatitis. Finally, Charpy[146] has the clinical impression that a daily dose of 100 mg. of vitamin C eliminated heat prostration in a group of 31 men working at temperatures of 100 to 120°F., but this observation is not in keeping with carefully controlled studies, which showed no increase in resistance to hot environments from the use of large amounts of vitamin C and other water-soluble vitamins.[98]

The cure of lupus vulgaris (tuberculosis of the skin) by massive doses of vitamin D, averaging 100,000 to 150,000 units per day for three months or longer, was first reported by Charpy[146] and Dowling[147] and was subsequently confirmed by numerous other investigations. The only adverse report is that of Ingram and Anning,[148] who observed cures in only 4 patients and improvement in 23 others out of 158 cases treated with massive doses of calciferol. There is no explanation for this divergence of results. In general, 60 to 75 per cent cure can be expected from this type of treatment.[149]

Charpy[146] believes that oral administration of the drug is superior to parenteral and that an alcoholic solution of vitamin D is more satisfactory than the oily solution, but others found that the route of administration and the type of vehicle for solution of the vitamin D made little difference in the results of therapy. Doses of 150,000 units per day were usually more effective than 100,000-unit doses, and an ineffective dose remained ineffective no matter how long it was continued.[147] There has been no correlation between clinical results and serum calcium levels.[150] During the first few weeks of treatment nearly every patient has a Herxheimer-like reaction, with increase in activity of the skin lesions, a more positive tuberculin test and an increase in erythrocyte sedimentation rate.[150, 151] Local treatment of the lesion at this time is important for good results.[151] The greatest clearing of the lesions occurs within four to eight months,[150] but Charpy[146] believes that treatment should be prolonged for a year or two because histologic cure is considerably slower than clinical remission. Toxic symptoms (to be discussed in a later section of this review) from such large doses of vitamin D were noted in 16 to 50 per cent of the cases treated,[147, 148, 150, 151] but Dowling[152] points out that often clinical improvement is most striking just when the patient is beginning to look and feel ill from the cumulative effect of treatment. Nephritis and arteriosclerosis contraindicate the use of vitamin D. The mode of action of vitamin D in lupus vulgaris has been much debated but is not understood.

The use of massive doses (100,000 to 900,000 units per day) of vitamin D in sarcoidosis has been tried on a limited scale[153, 154] with improvement or even clearing of the skin lesions but with marked toxic reactions. As a result, the benefit to be derived is questionable. Likewise, it has been recommended, after critical evaluation of the results of therapy, that the use of massive doses of vitamin D in rheumatoid arthritis is neither beneficial nor justified.[155]

The pharmacologic use of vitamin E has been the subject of much heated controversy, largely owing to the numerous, enthusiastic reports from Shute and his co-workers. Other investigators have been unable to confirm Shute's observations. Vogelsang, Shute and Shute[156, 157] claim to have treated 1500 patients with angina, rheumatic heart disease, hypertensive heart disease, congestive failure and other types of heart disease with 200 to 900 mg. of vitamin E per day. They state that vitamin E is the most effective known drug in heart disease and that 80 per cent of the patients treated improve to such an extent that they return to activity even after great disability. Vitamin E is said to decrease capillary permeability, produce capillary dilatation, reduce anoxia of the cardiac muscle, prevent and resolve thrombi and promote vascularization of scar tissue.[157] I do not believe that these actions of vitamin E have been proved, although Shute et al.[158] present an almost convincing review of the function of vitamin E based on biochemical and animal studies.

In a carefully controlled study that avoided both subjective impressions of the patients and natural variations in disease, Levy and Boas[159] found that daily doses of 200 to 800 mg. of vitamin E given for three to eleven weeks to 13 patients with angina pectoris were completely ineffective. Baer et al.[160] investigated the effect of 300 to 400 mg. of vitamin E per day for three to six months in 22 patients with various cardiac conditions and likewise observed no unequivocal evidence of improvement. Similar negative results were obtained by Donegan et al.[161] when they treated 21 cases of cardiovascular disease with vitamin E for five to twenty months. The consensus of medical opinion in the United States is on the side of the negative results from the use of vitamin E in heart disease, and it questions the validity of Shute's observations. On the other hand, the British opinion, as reflected by an editorial[162] that completely reviews all the therapeutic uses of vitamin E, holds that Shute's claims are plausible and that further controlled clinical tests are indicated.

Additional unconfirmed reports state that vitamin E is beneficial in the treatment of nephritis,[163] toxemias of pregnancy,[164] purpura,[165] the menopausal syndrome,[166] Dupuytren's contracture,[69] fibrositis,[167] various skin diseases of the degenerative collagenous group[168] and a host of peripheral vascular diseases.[162]

Aside from the treatment of prothrombin deficiency, there has been very little pharmacologic use of vitamin K. One report of the beneficial effect of 20 mg. twice a day in 8 cases of chilblains was made by Wheatley.[169] No prothrombin levels were obtained and improvement was measured by clinical response. The rationale for using vitamin K in this condition was based upon the assumption that in chilblains there may be increased permeability of the blood vessels and diminished coagulability of the blood. Another possible effect of vitamin K to be briefly noted is the observation that half of 15 cases with chronic essential hypertension had a significant reduction in blood pressure after oral or intravenous administration of Synkavite.[170]

In contrast with the lack of indications for wholesale vitamin supplementation on the basis of deficiency disease, the pharmacologic uses discussed above constitute a definite need for specific vitamins in certain diseases.

(To be concluded)

References

72. Blankenhorn, M. A. Deficiency diseases in Cincinnati General Hospital: ten-year study. *J. A. M. A.* **140**:1315-1317, 1949.
73. Bean, W. B., Vilter, R. W., and Blankenhorn, M. A. Incidence of pellagra: studies in Cincinnati General Hospital 1935-1947. *J. A. M. A.* **140**:872, 1949.
74. Darby, W. J., and Milam, D. F. Field study of prevalence of clinical manifestations of dietary inadequacy. *Am. J. Pub. Health* **35**:1014-1021, 1945.
75. Dogramaci, I. Scurvy: survey of 241 cases. *New Eng. J. Med.* **235**:185-189, 1946.
76. Cartwright, G. E., and Wintrobe, M. M. Hematologic survey of repatriated American military personnel. *J. Lab. & Clin. Med.* **31**:886-899, 1946.
77. Kark, R., Aiton, H. F., and Pease, E. D. Nutritional status of Japanese prisoners-of-war, Burma 1945. *Ann. Int. Med.* **25**: 266-269, 1946.
78. Hibbs, R. E. Beriberi in Japanese prison camp. *Ann. Int. Med.* **25**: 270-282, 1946.
79. Harrison, G. F. Nutritional deficiency, painful feet, high blood-pressure in Hong Kong. *Lancet* **1**:961-964, 1946.
80. Simpson, J. "Burning feet" in British prisoners-of-war in Far East. *Lancet* **1**:959-961, 1946.
81. Denny-Brown, D. Neurological conditions resulting from prolonged and severe dietary restriction (case reports in prisoners-of-war, and general review). *Medicine* **26**:41-113, 1947.
82. Ridley, H. Ocular manifestations of malnutrition in released prisoners-of-war from Thailand. *Brit. J. Ophth.* **29**:613-618, 1945.
83. Peraita, M. Deficiency neuropathies observed in Madrid during civil war (1936-9). *Brit. M. J.* **2**:784, 1946.
84. Kraemer, M. Clinical findings in American soldiers released from German prison camp. *Gastroenterology* **7**:191-198, 1946.
85. Davidson, C. S., Wilcke, H. L., and Reiner, P. J. Nutritional survey of starvation in group of young men. *J. Lab. & Clin. Med.* **31**:721-734, 1946.
86. Leyton, G. B. Effects of slow starvation. *Lancet* **2**:73-79, 1946.
87. Davidson, C. S., Wilcke, H. L., Fein, H. D., and Reiner, P. J. Nutrition survey of Viennese civilians under United States Occupation, 1945. *J. Lab. & Clin. Med.* **33**:1470-1481, 1947.
88. Borsook, H., and Wiehl, D. G. Nutritional status of aircraft workers in Southern California. V. Conspectus of survey and its field. *Milbank Mem. Fund Quart.* **24**:251-291, 1946.
89. Frazier, C. N. Personal communication.
90. Johnson, R. E. Personal communication.
91. Borsook, H., Dubnoff, J. W., Keighley, G., and Wiehl, D. G. Nutritional status of aircraft workers in Southern California. IV. Effects of vitamin supplementation on clinical, instrumental and laboratory findings and symptoms. *Milbank Mem. Fund Quart.* **24**:99-185, 1946.
92. Youmans, J. B., Patton, E. W., Robinson, W. D., and Kern, R. Analysis of corneal vascularization as found in survey of nutrition. *Tr. A. Am. Physicians* **57**:49-54, 1942.
93. Darby, W. J. Oral manifestations of iron deficiency. *J. A. M. A.* **130**:830-835, 1946.
94. Stamm, W. P., Macrae, T. F., and Yudkin, S. Incidence of bleeding gums among RAF personnel and value of ascorbic acid in treatment. *Brit. M. J.* **2**:239-241, 1944.
95. Leeson, H. J., Webb, J. F., Ferguson, H. P., Simmons, E. M., and McHenry, E. W. Study of ascorbic acid nutrition. *Canad. M. A. J.* **53**:341-344, 1945.
96. Linghorne, W. J., et al. Relation of ascorbic acid intake to gingivitis. *Canad. M. A. J.* **54**:106-119, 1946.
97. Keys, A. Human fitness and state of vitamin nutrition. *Nutrition Rev.* **5**:129-131, 1947.
98. Henschel, A., Taylor, H. L., Brozek, J., Mickelsen, O., and Keys, A. Vitamin C and ability to work in hot environments. *Am. J. Trop. Med.* **24**:259-265, 1944.
99. Glickman, N., Keeton, R. W., Mitchel, H. H., and Fahnstock, M. K. Tolerance of man to cold as affected by dietary modifications: high versus low intake of certain water-soluble vitamins. *Am. J. Physiol.* **146**:538-558, 1946.
100. Rafsky, H. A., and Newman, B. Nutritional aspects of aging. *Geriatrics* **2**:101-104, 1947.
101. Vernon, P. E., and McKinlay, M. Effects of vitamin and hormone treatment of senile patients. *J. Neurol., Neurosurg. & Psychiat.* **7**:87-92, 1944.
102. Ivy, A. C., Jung, F. T., Bing, F. C., and Cisler, L. Effect of administering vitamin supplement, in capsules, to groups of workers in steel industry. *Industr. Med.* **16**:163-167, 1947.
103. Bransby, E. R., Burn, J. L., Magee, H. E., and MacKecknie, D. M. Effect of daily vitamin supplements on health and development of children. *Brit. M. J.* **1**:193-197, 1946.
104. Richardson, J. A., and Kinard, F. W. Effect of vitamin A administration upon defective color vision. *South. M. J.* **39**:811-813, 1946.
105. Rundles, R. W. Diabetic neuropathy: general review with report of 125 cases. *Medicine* **24**:111-160, 1945.
106. Root, H. F., and Cruz Mascarenhas, C. Diet in uncontrolled diabetes preceding acute neuropathy. *Am. J. Digest. Dis.* **13**:173-177, 1946.
107. Sevringhaus, E. L. Role of vitamin therapy in management of diabetes mellitus. *Am. J. Digest. Dis.* **14**:193-195, 1947.
108. Volwiler, W. T., Jones, C. M., and Mallory, T. B. Criteria for measurement of results of treatment in fatty cirrhosis. *Gastroenterology* **11**:164-182, 1948.
109. Keeton, R. W., et al. Convalescence: study in physiological recovery of nitrogen metabolism and liver function. *Ann. Int. Med.* **28**:521-551, 1948.
110. Harrell, R. F. Mental response to added thiamine. *J. Nutrition* **31**: 283-298, 1946.
111. Robertson, E. C., Tatham, C. M., Walker, N. F., and Weaver, M. R. Effect of added thiamine on growth, vision, and learning, using identical twins. *J. Nutrition* **34**:691-700, 1947.
112. Porter, A. D., Godding, E. W., and Brunauer, S. R. Vitamin A in Darier's disease. *Arch. Dermat. & Syph.* **56**:306-316, 1947.
113. Leitner, Z. A., and Moore, T. Vitamin A in Darier's disease. *Brit. J. Dermat.* **60**:41-50, 1948.
114. Dublin, W. B., and Hazen, B. M. Relation of keratosis seborrheica and keratosis senilis to vitamin A deficiency. *Arch. Dermat. & Syph.* **57**:178-183, 1948.
115. Fisher, S. H., and Chamberlain, W. E. Roentgen and vitamin A therapy for treatment of warts: comparison of two methods and report of 315 treated cases. *Pennsylvania M. J.* **51**:151-155, 1947.
116. Leitner, Z. A., and Ford, E. B. Vitamin A and pityriasis rubra pilaris: with comment about genetrics. *Brit. J. Dermat.* **59**: 407-427, 1947.
117. Hyams, M. N., and Bloom, O. H. Leukoplakia vulvae: its etiology and results of treatment with vitamin A. *Am. J. Obst. & Gynec.* **53**:214-220, 1947.
118. Lynch, F. W., and Cook, C. D. Acne vulgaris treated with vitamin A. *Arch. Dermat. & Syph.* **55**:355-357, 1947.
119. Simkins, S. Use of massive doses of vitamin A in treatment of hyperthyroidism: preliminary report. *J. Clin. Endocrinol.* **7**: 574-585, 1947.
120. Swenson, R. E. Parenteral vitamin B as agent for determining arm-to-tongue circulation time. *Am. Heart J.* **32**:612-616, 1946.
121. Sexton, G. B., and Gowdey, C. W. Relation between thiamine and arsenical toxicity: preliminary report. *Arch. Dermat. & Syph.* **56**:634-647, 1947.
122. Ferreira-Marques, J. Contribution to study of etiology, pathogenesis, and treatment of pruriginous diseases. *Acta dermat.-vn.* **28** (Supp. 19): 1, 1948.
123. Gourlay, R. J. Problem of chilblains, with note on their treatment with nicotinic acid. *Brit. M. J.* **1**:336-339, 1948.
124. Oppenheim, A., and Lih, B. Peroral administration of vitamin B_6 (pyridoxine hydrochloride) in treatment of radiation sickness. *Radiology* **47**:381-385, 1946.
125. Wells, J. J., and Popp, W. C. Use of pyridoxine hydrochloride in treatment of radiation sickness: preliminary report. *Proc. Staff Mtrs., Mayo Clin.* **23**:482-486, 1947.
126. Lewy, A., and Fox, N. Pyridoxine (B_6) used in treatment of vertigo. *Arch. Otolaryng.* **46**:681-683, 1947.
127. Fishberg, E. H., and Vorzimer, J. Effect of pyridoxine on granulopenia caused by thiouracil. *Proc. Soc. Exper. Biol. & Med.* **60**: 181-184, 1945.
128. Knutson, D., Oldfelt, C. O., and Wising, P. Treatment of leukopenia and granulocytopenia with pyridoxine (vitamin B_6). *Acta med. Scandinav.* **125**:326-332, 1946.
129. Fox, J. T., and Tulliday, G. M. Pyridoxine (vitamin B_6) in epilepsy: clinical trial. *Lancet* **2**:345, 1946.
130. Hesseltine, H. C. Pyridoxine failure in nausea and vomiting of pregnancy. *Am. J. Obst. & Gynec.* **51**:82-86, 1946.
131. Goldman, L. Treatment of subacute and chronic discoid lupus erythematosus with intensive calcium pantothenate therapy. *J. Invest. Dermat.* **11**:95, 1948.
132. Flinn, L. B., Howard, J. W., Todd, C. W., and Scott, E. G. Para aminobenzoic acid treatment of Rocky Mountain spotted fever. *J. A. M. A.* **132**:911-915, 1946.
133. Ravenel, S. F. Para-aminobenzoic acid therapy of Rocky Mountain spotted fever: outline of comprehensive plan of treatment with report of five cases. *J. A. M. A.* **133**:989-994, 1947.
134. Greeley, D. M. Treatment and prevention of Rocky Mountain spotted fever in children. *M. Clin. North America* **31**:647-658, 1947.
135. Kelsey, W. M., and Harrell, G. T. Management of tick typhus (Rocky Mountain spotted fever) in children. *J. A. M. A.* **137**: 1356-1361, 1948.
136. Tierney, N. A. Effect of para-aminobenzoic acid in rickettsial diseases. *South. M. J.* **40**:81-83, 1947.
137. Levy, M. D., and Arnold, W. T. Para-aminobenzoic acid in treatment of endemic typhus fever. *Texas State J. Med.* **42**:314-316, 1946.
138. Zarafonetis, C. J. D. Therapeutic possibilities of para-aminobenzoic acid. *Ann. Int. Med.* **30**:1188-1211, 1949.
139. May, H. B., and Vallance-Owen, J. Para-aminobenzoic acid in leukaemia: effect on leucocyte count. *Lancet* **2**:607-609, 1948.
140. Dry, T. J., Butt, H. R., and Scheifley, C. H. Effect of oral administration of para-aminobenzoic acid on concentration of salicylates in blood: preliminary report. *Proc. Staff. Mett., Mayo Clin.* **21**: 497-504, 1946.
141. Salassa, R. M., Bollman, J. L., and Dry, T. J. Effect of para-aminobenzoic acid on metabolism and excretion of salicylate. *J. Lab. & Clin. Med.* **33**:1393-1401, 1948.
142. Berman, L. Human thyrotoxicosis: response to para-aminobenzoic acid. *Proc. Soc. Exper. Biol. & Med.* **59**:70-72, 1945.
143. Carnick, M., Polis, B. D., and Klein, T. Methemoglobinemia: treatment with ascorbic acid. *Arch. Int. Med.* **78**:296-302, 1946.

144. Chapman, D. W., and Shaffer, C. F. Mercurial diuretics: comparison of acute cardiac toxicity in animals and effect of ascorbic acid on detoxification in their intravenous administration. *Arch. Int. Med.* **79**:449-456, 1947.
145. Klasson, D. H. Ascorbic acid in treatment and prevention of poison oak dermatitis. *Arch. Dermat. & Syph.* **56**:864-867, 1947.
146. Charpy, J. Vitamin D₂ in treatment of cutaneous tuberculosis. *Brit. J. Dermat. & Syph.* **60**:121-127, 1948.
147. Dowling, G. B., and Thomas, E. W. P. Treatment of lupus vulgaris with calciferol. *Lancet* **1**:919-922, 1946.
148. Ingram, J. T., and Anning, S. T. Treatment of lupus vulgaris with large doses of calciferol: clinical appraisal. *Brit. J. Dermat. & Syph.* **60**:159-164, 1948.
149. Editorial. Lupus vulgaris and vitamin D. *Brit. M. J.* **1**:455, 1948.
150. Dowling, G. B., Gauvain, S., and Macrae, D. E. Vitamin D in treatment of cutaneous tuberculosis. *Brit. M. J.* **1**:430-435, 1948.
151. Macrae, D. E. Calciferol treatment of lupus vulgaris. *Brit. J. Dermat. & Syph.* **59**:333-338, 1947.
152. Dowling, G. B. Vitamin D in treatment of cutaneous tuberculosis. *Brit. J. Dermat. & Syph.* **60**:127-131, 1948.
153. Curtis, A. C., Taylor, H., Jr., and Grekin, R. H. Sarcoidosis: results of treatment with varying amounts of calciferol and dihydrotachysterol. *J. Invest. Dermat.* **9**:131-150, 1947.
154. Robertson, R. F. Vitamin D in Boeck's sarcoidosis. *Brit. M. J.* **2**: 1059-1061, 1948.
155. Hench, P. S., et al. Rheumatism and arthritis: review of American and English literature of recent years. *Ann. Int. Med.* **28**:66-168 and 308-451, 1948.
156. Vogelsang, A. B., Shute, E. V., and Shute, W. E. Vitamin E in heart disease: general remarks. *M. Rec.* **160**:279-284, 1947.
157. *Idem.* Some medical uses of vitamin E. *M. Rec.* **161**:83 and 155, 1948.
158. Shute, W. E., Shute, E. V., and Vogelsang, A. Physiological and biochemical basis for use of vitamin E in cardiovascular disease. *Ann. Int. Med.* **30**:1004-1008, 1949.
159. Levy, H., and Boas, E. P. Vitamin E in heart disease. *Ann. Int. Med.* **28**:1117-1124, 1948.
160. Baer, S., Heine, W. I., and Gelfond, D. B. Use of vitamin E in heart disease. *Am. J. M. Sc.* **215**:542-547, 1948.
161. Donegan, C. K., Messer, A. L., and Orgain, E. S. Negative results of tocopherol therapy in cardiovascular disease. *Am. J. M. Sc.* **217**:294-299, 1949.
162. Editorial. Vitamin E therapy. *Lancet* **2**:857, 1948.
163. Shute, W. E. Three cases of acute nephritis treated with vitamin E. *Urol. & Cutan. Rev.* **50**:679, 1946.
164. Shute, E. V. Non-eclamptic late toxemias treated by vitamin E. *Am. J. Surg.* **71**:470-478, 1946.
165. Skelton, F., Shute, E. V., Skinner, H. G., and Waud, R. A. Anti-purpuric action of α-tocopherol (vitamin E). *Science* **103**:762, 1946.
166. Ferguson, H. E. Use of vitamin E in menopausal syndrome. *Virginia M. Monthly* **75**:447, 1948.
167. Steinberg, C. L. Fibrositis (muscular rheumatism) including Dupuytren's contracture: new method of treatment. *New York State J. Med.* **47**:1679-1682, 1947.
168. Burgess, J. F. Vitamin E (tocopherols) in collagenoses. *Lancet* **2**: 215-217, 1948.
169. Wheatley, D. P. Vitamin K for relief of chilblains. *Brit. M. J.* **2**: 689-691, 1947.
170. Rosenthal, N., and Shapiro, S. By-effects of anti-hemorrhagic quinones: antipressor action in chronic hypertension in man. *J. Pharmacol. & Exper. Therap.* **85**:294-298, 1945.

CASE RECORDS OF THE MASSACHUSETTS GENERAL HOSPITAL

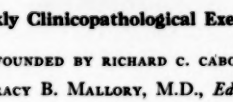

Weekly Clinicopathological Exercises

FOUNDED BY RICHARD C. CABOT

TRACY B. MALLORY, M.D., *Editor*

BENJAMIN CASTLEMAN, M.D., *Associate Editor*

EDITH E. PARRIS, *Assistant Editor*

CASE 35511

PRESENTATION OF CASE

First admission. A sixty-seven-year-old man was admitted to the hospital complaining of three episodes of terminal hematuria within the past two years, the last episode occurring four months prior to admission.

For four months, the patient had noted slightly increased frequency and occasional dribbling, but had no nocturia, pain, or retention. Physical examination at the time of admission was negative. The urine had a specific gravity of 1.022 and gave a + test for albumin, with occasional red and white cells in the sediment. The nonprotein nitrogen was 27 mg. per 100 cc. An intravenous pyelogram showed good kidney function bilaterally. The ureters were normal, but a slight deformity was noted at the base of the bladder.

On cystoscopy a 1.5-cm. papillary tumor was seen just above the left ureteral orifice, and there were scattered small tumor implants elsewhere. Colon bacilli were grown from the catheterized urine. The primary tumor and implants were fulgurated and 8 1-millicurie-radon seeds were implanted above the left ureteral orifice. The patient was discharged much improved. The pathological report of the bladder tumor was carcinoma, Grade III.

Second admission (one month later). Three weeks prior to readmission external radiation therapy was begun at another hospital, following which the patient noted frequency and dysuria. For two days before admission he was nauseated and vomited. On the day of admission he had two shaking chills, a temperature of 102°F., right-flank pain and costovertebral-angle tenderness.

Physical examination was unchanged. The urine had a specific gravity of 1.014 and gave a ++++ test for albumin, and the sediment was loaded with red cells and pus. *Staphylococcus aureus* was recovered on culture. The nonprotein nitrogen was 34 mg. per 100 cc. An intravenous pyelogram showed good kidney function, a smooth bladder outline and some dilatation of the lower end of the left ureter. Following treatment with sulfathiazole the symptoms subsided, and the patient was discharged to continue sulfonamides at home.

Third admission (five years later). After two uneventful years the patient again began to have intermittent hematuria, either primary or total, occurring in widely spaced episodes lasting up to two days. There were also nocturia and slight dysuria. On admission the urine had a specific

gravity of 1.014 and gave a ++ test for albumin; the sediment contained many red and white cells, and yielded *Staph. albus* on culture. Three grams of prostatic chips obtained by transurethral resection showed stromal hyperplasia. The bladder outlet was noted to be irregularly contracted at the time of operation, but no recurrence of tumor was seen.

Fourth admission (six weeks later). The patient was then well except for one bout of hematuria. The night before this admission he felt chilly, had left-flank pain, passed liquid and then clotted blood and went into acute retention. On admission the white-cell count was 14,000. The urine had a specific gravity of 1.012, gave a +++ test for albumin, was loaded with pus and yielded *Staph. aureus* and *Staph. albus* on culture. Intravenous pyelograms showed good function on the right, impaired excretion on the left, and dilatation of the lower left ureter. The patient responded to catheterization and sulfonamide therapy and was discharged improved after twelve days.

Fifth admission (one year later). After about six months there was still another recurrence of episodic hematuria every two or three weeks and the onset of hesitancy and a weak stream. On several occasions, clots in the bladder necessitated catheterization. On this admission the urine had a specific gravity of 1.016, gave a + test for albumin and contained *Staph. albus* and many red cells. The temperature was normal, and the white-cell count 10,800. Following spontaneous passage of a large clot the urine cleared, and the patient was discharged.

Sixth admission (three months later). Following discharge there were two short episodes of hematuria. On the day before admission the urine became scanty and grossly bloody, with large clots. On physical examination the bladder was percussed half way to the umbilicus. The urine had a specific gravity of 1.022 and contained much albumin and red cells. Immediately following admission the temperature rose to 101°F. and for the next week spiked to between 100 and 102°F. daily. The white-cell count was 14,400. Two 500-cc. whole-blood transfusions were given following hemoglobin determinations of 10.5 and 9.7 gm. The nonprotein nitrogen of 56 mg. per 100 cc. on admission rose steadily to a high of 135 mg. and then subsided gradually to 84 mg. on discharge. Fluoroscopy showed elevation of the left leaf of the diaphragm and some atelectasis of the left lower lobe of the lung. There was also aching left-flank pain. Cystoscopy demonstrated multiple small areas of hemorrhage in the bladder mucosa but no recurrence of the tumor. The right ureteral orifice was crescentic, and the left could not be visualized. The patient was maintained on intravenous feedings, penicillin and streptomycin. The urine cleared, and output was good. The patient left improved after six weeks of hospitalization.

Final admission (one month later, about seven years since the first admission). The patient was then well for three weeks, when hematuria and passage of clots recurred. On admission the urine had a specific gravity of 1.012 and contained much albumin, red cells, pus and bacteria. The nonprotein nitrogen was 45 mg. per 100 cc. The white-cell count was 7000, and the hemoglobin 9.2 gm., and the patient was given 500 cc. of whole blood. The intravenous pyelogram showed good function of the right kidney, the cortex of which was noted to be thin. No excretion could be detected on the left.

On the ninth hospital day a bilateral ureterocutaneous anastomosis was done, following which the patient passed moderate amounts of urine from the right kidney and small amounts from the left. The nonprotein nitrogen began to climb, reaching 98 mg. per 100 cc. There was onset of diarrhea; guaiac-positive stools were noted. The white-cell count began to rise, and the hemoglobin remained low. On the sixteenth hospital day the patient had a shaking chill and began vomiting. Urinary output declined markedly. Returns from bladder irrigation consisted of foul-smelling, semisolid material.

During the last week of the hospital stay, the temperature spiked to 103°F. and then declined to normal. The patient died on the twenty-third hospital day.

Differential Diagnosis

Dr. George G. Smith*: This patient's complaint on admission was three episodes of terminal hematuria. I want to speak of the significance of terminal hematuria. With initial hematuria in a man over fifty, within the prostatic age, the chances are that the blood is coming from the prostatic urethra; if it is terminal hematuria, it probably is from the bladder, whereas renal hematuria usually gives total discoloration of the urine.

Nothing is said here about a rectal examination or about the amount of residual urine.

The frequency and dysuria on the second admission might have been due to x-ray treatment if he had had enough to cause congestion of the bladder mucosa. The costovertebral-angle tenderness sounds as if he had an attack of acute pyelonephritis on the right side.

At the third admission we are again kept in the dark about what the prostate felt like and how much residuum the patient had, but it is evident that he had prostatic obstruction since a transurethral resection was performed.

About six years after the tumor of the bladder was treated, the bladder apparently was free of tumor. It would make the diagnosis easier if we

*Member, Board of Consultation (formerly, chief of Urology Service), Massachusetts General Hospital.

were told where the blood was coming from and if the patient was cystoscoped.

Again, on the fourth admission, we have no information of the cause of the hematuria. Among other things, it might have come from the remnant of the prostate left behind at transurethral resection. It is not unusual to have episodes of hematuria occasionally, even for several years after transurethral resection.

A marked elevation of nonprotein nitrogen points definitely to bilateral renal involvement. At first sight it seems as if the cause of death in this patient would be easy to put one's finger on. I think he died chiefly from pyelonephritis.

He had had one previous attack of infection on the right side and now showed evidence of marked infection, with pain, elevation of the left leaf of the diaphragm and entire destruction of the function of the left kidney. I believe that probably was the result of implantation of the radium near the ureteral orifice. One can postulate swelling of the radium-affected tissue and infection traveling up the lymphatics of the ureter, bringing about the combination of infection and obstruction, which led to pyelonephritis with a gradual destruction of the kidney on the affected side. There is nothing in the history to explain obstruction of the lower right ureter, and yet one of the late intravenous pyelograms showed that the right kidney had a thin cortex; this probably was the result of repeated attacks of pyelonephritis.

Let us look at one or two of the intravenous pyelograms.

Dr. James J. McCort: An intravenous pyelogram made on the first admission shows the kidneys to be within normal limits in size and shape; both are satisfactorily outlined. After intravenous administration Diodrast was excreted in good concentration within five minutes. The pelves and calyxes are not dilated. The films taken at fifteen minutes confirm this impression, but the film of the bladder at thirty minutes shows a slight irregularity on the left inferior margin of the bladder. A film of the bladder after evacuation again shows this slight irregularity.

Dr. Smith: It is rather difficult to explain why the patient was not definitely improved by his skin ureterostomies. I do not know whether he had catheters put up to the kidneys or drainage without catheters, which we sometimes do. We can often clear up or alleviate the effects of marked pyelonephritis by adequate drainage of the kidney pelvis by means of nephrostomy, pyelostomy or ureterostomy. But in this case the drainage did not accomplish this. It makes me think that there was another factor involved besides obstruction of the lower ureter. The pyelonephritis may have been too far advanced to be relieved by drainage alone.

Another thing that ought to be explained is the repeated attacks of hematuria. In fact, this was really the chief item in the past history. At the sixth admission, cystoscopy showed multiple small areas of hemorrhage in the bladder mucosa. Whether the blood came down the left ureter and indicated a carcinoma of the left renal pelvis or ureter, I do not know, but it would explain the bleeding. No tumor was found in the bladder. However, the wall of a bladder that has been chronically inflamed for a long time will sometimes bleed so that one has to do a cystostomy. I remember 2 cases in which it was necessary to do a total cystectomy to stop bleeding.

An item that I think is important is that the tumor was classified as Grade III. That is significant and means that it was an unusually malignant tumor even though it did not recur in a period of seven years. It is perfectly possible, and I think probable, that the lesion extended from the largest tumor here into the bladder wall, which may account for the fact that when the bladder was examined cystoscopically bleeding areas were seen in the bladder mucosa.

The picture that Dr. McCort showed us is suggestive of a mass behind the bladder and more or less around the bladder neck. The dilatation of the right kidney, which was due, perhaps, to pyelonephritis, may also have been due to obstruction of the lower end of the ureter by a malignant lesion involving the bladder wall or coming up behind the bladder. The elevation of the left leaf of the diaphragm and the aching pain around the left kidney may indicate perinephritic abscess secondary to the severe left renal infection. I believe that if this man had been cured of his cancer the first time it was treated, as he appeared to be, and even if his left kidney had been destroyed by the effect of radium at the lower end of the ureter or from some other reason, the right kidney would have carried on adequately. But the right kidney evidently was seriously damaged. Later on, after a number of years, if this patient did have carcinoma that extended into the bladder wall and around the base of the bladder, it is more than likely that he had metastases to the aortic lymph nodes, and possibly in the lung — a disseminated carcinomatosis. My impression is that death was primarily due to pyelonephritis, but he probably had extensive carcinoma and certainly obstruction to the lower ureters.

Dr. Fletcher H. Colby: This patient is very interesting from certain points of view. It is not quite clear in the protocol that he had a great deal of external radiation. He was one of the early patients given external radiation on the 1200-kilovolt machine at the Huntington Memorial Hospital. In addition he had a large amount of interstitial radiation in the bladder tumor. This man, as I remember, had about 12,000 r of external radiation at

the time, or soon after the radium was implanted, so that he was given an unusual dose of both external and internal radiation. I do not think Dr. Smith appreciated the fact that he had had so much radiation to his bladder; that might have made a difference in the way he thought about the bleeding.

DR. SMITH: Yes.

DR. COLBY: The patient was followed carefully in the seven or eight years after the initial tumor was treated in this way. I may add also that when he was first seen a sufficient amount of induration was felt on bimanual examination so that it was believed that this tumor probably involved the whole thickness of the bladder wall. It was subsequently shown that that was not true. At any rate, the patient was cystoscoped on many occasions following that, and at no time was the slightest evidence of recurrence of the primary bladder neoplasm seen. He had a sufficient amount of difficulty in voiding so that a transurethral resection was done on the prostate. I think the difficulty was due to contraction of the bladder neck rather than real prostatic hypertrophy. At no time did the prostate feel very large, and the bleeding subsequently was definitely not from the area of resection. It was a diffuse bleeding from all over the bladder, and at no time, even when he was actively bleeding, was any blood seen by cystoscope coming from either one of the ureteral orifices. It was again perfectly obvious on clinical examination that this man had progressive fibrosis of the bladder involving both ureteral orifices, more on the left, which had radium planted nearby, than on the right, but both orifices were involved in disease.

DR. MCCORT: Did you specify the tumor dose as 12,000 r?

DR. COLBY: That was the dose measured in air.

DR. MCCORT: The actual tumor dose was therefore about 6000 or 7000 r.

DR. COLBY: The external radiation was so extensive that this man was practically incontinent of urine for months.

DR. SMITH: I think it is worth saying that I have seen some patients who have been treated with extensive radiation, both internal and external, and after some years the ureters became fibrosed into a spindle-shaped canal, which gradually became obstructed. They usually go on all right after that. I suppose that happened to this patient's ureters. I think it would have made a little difference in my consideration of the case if I had realized that he had had more than the conventional dosage of x-ray because that would have explained the ureteral obstruction.

CLINICAL DIAGNOSES

Carcinoma of bladder.
Radiation fibrosis of bladder.
Uremia.

DR. SMITH'S DIAGNOSES

Pyelonephritis, bilateral.
Obstruction of lower ureters by tumor.

ANATOMICAL DIAGNOSES

(*Carcinoma of bladder cured by radiation.*)
Radiation fibrosis of bladder and ureters.
Papillary carcinoma, Grade III, left renal pelvis.
Pyelonephritis, acute and chronic, bilateral.
Pelvic abscess, small.

PATHOLOGICAL DISCUSSION

DR. TRACY B. MALLORY: At post-mortem examination we found no evidence of metastatic or recurrent tumor in the bladder. The bladder wall was fibrotic. Both ureters were bound in a heavy mass of scarred tissue, and it was very difficult to trace the right one more than about 3 cm. from the ureteral orifice. The left ureter ended in an abscess cavity, 3 cm. in diameter. The surprise of the autopsy was that a large part of the left kidney was replaced with tumor. It was a papillary carcinoma of the renal pelvis, filling the pelvis and extensively invading the renal tissue. The remainder of that kidney was virtually destroyed by pyelonephritis. The right kidney was free from tumor but showed almost as extensive infection. We could find no evidence that the bladder tumor had extended or recurred, and I believe that this tumor of the renal pelvis was an entirely independent separate tumor.

DR. SMITH: That did not show in the early intravenous pyelograms.

DR. COLBY: I do not believe that the tumor of the left kidney was an essential factor in the production of symptoms. The essential feature was the fact that here was a man whose bladder cancer was definitely cured by radiation. But it is the exception, and, not to mince words, the cure was as lethal as his original disease. We had always believed in treating these patients with cancer by external radiation that it was an agent to be used cautiously not with the idea that it would be curative, simply palliative. Although this patient was cured of the cancer, we wonder if the effects of radiation resulted in his death.

CASE 35512

PRESENTATION OF CASE

A sixty-two-year-old man entered the hospital for study.

About six years before admission, the patient began having recurrent attacks of five to ten minutes' duration in which there were involuntary jerking movements on the right, beginning in the face and spreading to the right arm and then to the leg. The patient was unable to speak during the attacks but did not lose consciousness. Between

attacks he felt entirely well. However, as time went on, the attacks slowly increased in frequency. Two years before admission, he entered a community hospital, where no abnormalities were found on examination. He was discharged on anticonvulsive medication, which he took irregularly. About six months before admission, the patient began to be confused. Two months before admission, his wife noticed that he tended to drag the right leg slightly in walking. The seizures meanwhile became progressively more frequent, occurring two or three times a day in the two months before admission. There was no change in the character of these attacks. Throughout the illness, the patient had no headaches and had not felt ill. About a month before admission, he re-entered the same community hospital. His general physical condition was good, and there were no abnormalities on routine physical examination. Neurologic examination disclosed impaired ability to understand commands, recent poor memory and confusion as to the chronology of his life and his illness, although he was oriented as to date and place. He was able to read, write and name objects. The right fundus was normal except for moderate arteriosclerosis; the left fundus could not be seen because of cataract. Visual acuity was normal in the right eye. Confrontation fields were full. The right pupil was slightly larger than the left; both reacted normally to light and on convergence. Ocular movements were normal. There was slight right lower facial weakness on both volitional and emotional movement. The other cranial nerves were intact. There was falling away of the right arm and leg when outstretched, and on walking the right leg moved stiffly and over a smaller range than the left. The tendon reflexes were more active on the right, the plantar reflexes were normal. There were no sensory changes, although the patient was not sufficiently co-operative for refined testing.

X-ray films of the skull were normal. The spinal-fluid pressure was equivalent to 130 mm. of water, with no cells, and the protein was 44 mg. per 100 cc. The Wassermann reaction was negative. An electroencephalogram showed a "definite slow-wave focus" in the left posterior frontoparietal region. Admission to the Massachusetts General Hospital for further study was recommended.

On physical examination the findings were essentially as before. At this time, however, he was disoriented in time and place. He tended to perseverate on commands. The right pupil measured 3 mm., and the left 2.5 mm. Right lower facial weakness and the falling away of the outstretched right arm and leg were again observed. The tendon reflexes were slightly more active on the right, the abdominal reflexes present and equal, and the plantar reflexes fewer. There was some loss of position sense in the toes, more on the right. The general physical examination again was negative.

FIGURE 1. *Pneumoencephalogram.*
Arrows point to abnormal operation of the bodies of the lateral ventricles (note the slight ventricular shift to the right).

The routine laboratory studies were negative. Arteriography showed a normal vascular pattern. Pneumoencephalography revealed some shift downward of the left lateral ventricle and displacement of the third ventricle to the right (Fig. 1 and 2).

On the fifteenth hospital day an operation was performed.

DIFFERENTIAL DIAGNOSIS

DR. JAMES B. AYER*: This sixty-two-year-old man gave a consecutive history over a period of six years of Jacksonian epilepsy on the right side, increasing in frequency to two or three times daily and presumably not influenced by medication.

*Member, Board of Consultation (formerly, chief of Neurology Service), Massachusetts General Hospital.

For six months he had been confused in thought, and latterly had shown memory loss, difficulty in comprehension, disorientation and perseveration. No note is made of motor aphasia or of agnosia. Recently, there was evidence of right hemiparesis, as shown by lagging of the right side of the face, drifting of the hand (not due to sensory loss) and stiffness of the leg, with active tendon reflexes of this side. So far the evidence indicates a progressive lesion involving the left frontal lobe, invading or compressing the motor strip. The electroencephalogram corroborates this.

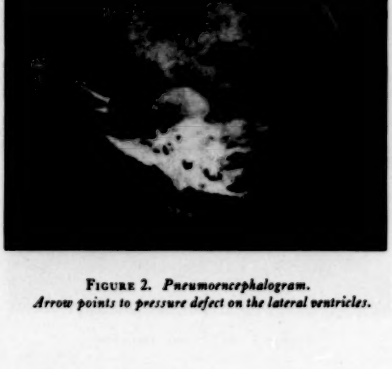

FIGURE 2. *Pneumoencephalogram.*
Arrow points to pressure defect on the lateral ventricles.

Although there was no headache, no choked disk and a normal spinal-fluid pressure, the shift of the left lateral ventricle and third ventricle proves that the lesion was an expanding one. In slowly growing tumors of the frontal lobe especially, we not infrequently fail to have the clinical evidence of pressure.

May I see the x-ray films? I hate to let a single laboratory procedure influence me too much, but with a pneumoencephalogram as definite as this, we must pay heed to it.

DR. JOSEPH HANELIN: I do not believe the encephalograms have been fully described. This is an anteroposterior film (Fig. 1), showing air within the anterior portions of the bodies of the lateral ventricles. There is an abnormal separation between the superior portions of the bodies of the lateral ventricles. The inner surface of the left lateral ventricle in the region of the separation is concave. There is a definite shift of the ventricle systems to the right side. The third ventricle is displaced only slightly to the right. The lateral films (Fig. 2) corroborate essentially what has been said about the anteroposterior view, and show an indentation superiorly upon the bodies of the lateral ventricles. The arteriograms were not very helpful in this case. There was no obvious midline shift of the cerebral vessels, and I cannot be sure of a localized deformity.

DR. AYER: On seeing these films I think it is fair to say that the changes in the encephalogram could not have been brought about by any lesion except an expanding one. Although the exact location is not too evident, there is some evidence that the lesion separated the ventricles and further evidence that there was a dislocation to the right and that the ventricle on the affected side was smaller, at least in the anteroposterior view. We must now admit that, in spite of absence of symptoms of increased intracranial pressure, we have definite evidence of an expanding lesion involving the frontal and parietal regions. Against its origin in the parietal area, suggested by early Jacksonian seizures, is the tardy advent of paralysis. Against its origin at the brain base is absence of signs of pressure on optic nerves or visual pathways.

That brings us to the pathologic possibilities. The commonest causes of tumor with a focus in the frontal lobe or frontoparietal region are two: a slowly growing glioma (I think we would have to say six years is fairly long) and meningioma. Of the meningioma group about half probably arise from the sphenoidal ridge and therefore cause early symptoms referable to the base of the brain. Meningiomas may arise from the region of the falx and grow down, displacing the brain on one side or both sides, which is perhaps indicated a little by this widening of the lateral ventricle although it was not mentioned in the protocol. One of these two tumors would be by far the most likely cause of an expanding lesion in this region.

Of the other possibilities that have to be considered, we may exclude embolism, thrombosis and hemorrhage, even when encapsulated, and also subdural hematoma, always a bugbear to the neurol-

ogist or the neurosurgeon, for these could hardly have led to such long-standing progressive symptoms.

An abscess could have grown like a tumor. We have no history of underlying infection. We have no evidence for septic embolism, and no sinus infection is recorded. Fever is not necessary, but cells in the spinal fluid are characteristically found in abscess; nor is abscess likely to give this continuous picture.

I suppose we ought to mention a few rare things, because if I make a diagnosis of something common, I am often wrong at these clinics. Gumma should be considered, although it is usually close to the surface; yet it can grow inward. The serologic reaction may or may not be positive; none is given here. I should put a gumma very far down the list. Cysticercus in the frontal lobe occurs but is a surprise finding in this part of the world. Hemangioma must be considered as a possibility, but seemingly it is ruled out or made most unlikely by the angiogram, which should show large and abnormal blood channels.

I am forced to say, therefore, that my choice rests between one of the two common glial tumors — probably astrocytoma, which is more slowly growing than glioblastoma — and meningioma. If this was a glioma it must have grown from an intracerebral location and extended toward the vertex to separate the ventricles; it probably extended into the corpus callosum to explain some of the mental symptoms. If it was meningioma it should have originated in the meninges over the vertex and grown downward or taken origin from the falx.

The operation was probably a bone flap to remove tumor if possible, but the tumor should have been a large one, and probably not removable in toto.

Dr. J. C. White: I am sorry that Dr. Ballantine is not here; he was the surgeon who operated. There are a few points that I would like to bring out. We thought, as Dr. Ayer pointed out, that the long history meant that this probably was an expanding tumor. Tumors, if they grow slowly enough, may become large without raising intracranial pressure. If this were an astrocytoma, we believed the chances of helping him were rather remote. If it were a meningioma, operation had a good chance of helping the seizure greatly. The astrocytomas have not responded well to operative intervention as far as seizures are concerned. If subject to seizures, over half the patients with meningiomas are relieved of them following removal of the tumor. We discussed the problem with the family, and in view of the desperate condition they said that we should take any chance. That is why operation was done. Dr. Ballantine operated, and Dr. Bidwell assisted him.

Clinical Diagnosis

Brain tumor: ? astrocytoma, ? meningioma.

Dr. Ayer's Diagnosis

Brain tumor: left frontal, probably glioma, possibly meningioma.

Anatomical Diagnosis

Glioblastoma multiforme of corpus callosum, probably arising from astrocytoma.

Pathological Discussion

Dr. Robinson L. Bidwell, II: We did a bone flap on the left side, crossing the midline slightly to the right. Upon the reflexion of the dura, tumor in the left precentral region next to the midline body was immediately evident, and that was biopsied for frozen section. While we were awaiting the report, the operation was continued. As we went down, tumor outcropping on the surface was evident almost all the way down to the corpus callosum. The tumor was soft and not sharply defined at the margins. Because it was an obvious glioma and could not be excised the operation was stopped. The report that came back to the operating room was glioma, probably astrocytoma. Postoperatively, the patient did poorly, developed pulmonary symptoms and died three days later.

Dr. Charles S. Kubik: At post-mortem examination there were indications of greatly elevated intracranial pressure consisting of flattening of the convolutions, and temporal and cerebellar pressure cones. Coronal section at the level of the mammillary bodies disclosed a pinkish-gray tumor of the corpus callosum of rather firm, rubbery consistence involving chiefly the left side, but extending across the midline to the other side, and this accounted for the spreading apart and flattening of the lateral ventricle visualized in the ventriculogram. The tumor extended for a considerable distance laterally into the white matter of the left hemisphere and also anteriorly and posteriorly

(Fig. 3). There was no line of demarcation between tumor and brain tissue. The gross appearance was fairly typical of astrocytoma. There were numerous hemorrhages in the midbrain; these are found in most cases of increased intracranial pressure with large herniations of the temporal lobe through the tentorial notch.

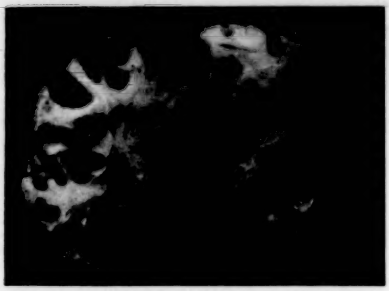

FIGURE 3. *Gross Specimen.*
Arrows point to gross limitations of tumor.

Histologically, the tumor was interesting. Parts of it, composed of fairly well differentiated astrocytes, would ordinarily be classified as astrocytoma; other parts were typical of glioblastoma multiforme. The history was much longer than is usually the case in glioblastoma multiforme, and I should suppose that this was a case in which an astrocytoma had recently undergone a change to a more malignant type of tumor. We have had two or three other examples of the same kind. In a case with a twelve-year history, an astrocytoma of the cerebellum was found at operation. There was rapid recurrence of symptoms, and a second operation disclosed glioblastoma multiforme. We have had a number of cases of glioma of the corpus callosum. They have usually been associated with convulsive seizures, not infrequently Jacksonian in type presumably because the tumor involved one hemisphere more than the other, as in this case. Another symptom, not invariably present, has been impairment of memory and confusion; one patient, however, a young man attending the Harvard Business School a good many years ago, made a very good showing in a stiff examination just before entering the hospital. In that case there was a glioblastoma multiforme of the corpus callosum much larger than this.

DR. STANLEY COBB: How do you explain the original low spinal-fluid pressure?

DR. KUBIK: The tumor was situated anteriorly and may have been slowly growing, and there were probably factors that we do not know about. One may also ask in a case like this whether the reading obtained at lumbar puncture represented the true pressure.

The New England
Journal of Medicine

Formerly
The Boston Medical and Surgical Journal
Established 1828

Official Organ of
THE MASSACHUSETTS MEDICAL SOCIETY
and
THE NEW HAMPSHIRE MEDICAL SOCIETY
OWNED BY THE MASSACHUSETTS MEDICAL SOCIETY AND PUBLISHED WEEKLY UNDER THE JURISDICTION OF THE COMMITTEE ON PUBLICATIONS

Richard M. Smith, M.D., *Chairman*
James P. O'Hare, M.D. Conrad Wesselhoeft, M.D.
Oliver Cope, M.D. John Fallon, M.D.
Joseph Garland, M.D., EDITOR
ASSOCIATE EDITORS
Thomas H. Lanman, M.D. Donald Munro, M.D.
Henry Jackson, Jr., M.D.
Clara D. Davies, EXECUTIVE EDITOR
Robert O'Leary, ASSISTANT EDITOR
EDITORIAL BOARD
C. Guy Lane, M.D. Maxwell Finland, M.D.
Henry R. Viets, M.D. Carroll B. Larson, M.D.
Robert M. Green, M.D. C. Stuart Welch, M.D.
Dwight O'Hara, M.D. Vernon P. Williams, M.D.
Fletcher H. Colby, M.D. Benjamin Castleman, M.D.
Robert L. Goodale, M.D. Hugh R. Leavell, M.D.
Chester M. Jones, M.D. J. Englebert Dunphy, M.D.
Harvey R. Morrison, M.D. Charles H. Burnett, M.D.

SUBSCRIPTION TERMS: $7.00 per year in advance, postage paid, for the United States (medical students, $4.00 per year); Canada, $8.00 per year (Boston funds); $9.50 per year for all foreign countries belonging to the Postal Union.

MATERIAL should be received not later than noon on Thursday, three weeks before date of publication.

THE JOURNAL does not hold itself responsible for statements made by any contributor.

COMMUNICATIONS should be addressed to the *New England Journal of Medicine*, 8 Fenway, Boston 15, Massachusetts. Telephone KE 6-2094.

NOBEL PRIZE IN MEDICINE

THE Nobel Prize for 1949 in medicine has been awarded jointly to two scientists, both investigating the function of the brain. Dr. Egas Moniz, a former professor of neurology in the University of Lisbon, developed cerebral angiography and made the procedure one of practical value in the diagnosis of brain tumor and blood-vessel abnormalities, and in addition devised the revolutionary brain operation of prefrontal leukotomy, later known as lobotomy, now widely used in the treatment of certain forms of mental disease. Dr. W. R. Hess, director of the Physiological Institute of Zurich University, has shown by animal experimentation the regulatory effect of the brain stem, through its peripheral projections by way of the autonomic nervous system, on such bodily processes as circulation, respiration, digestion, muscular action and psychic response. In the field of mental activity, Hess was able to produce artificial sleep by electrical stimulation of the diencephalon, thus indicating that some psychic processes, at least, are under brain-stem control and not entirely dominated, as previously postulated, by the cerebral cortex. Although the work of Hess is less spectacular than that of Moniz, with less immediate clinical application, the research emanating from the Zurich laboratory has greatly affected the physiologic and psychiatric thinking throughout the world.

The revolutionary contribution of Moniz was announced quietly to an unsuspecting world. Lisbon was not a "center of research," such as London, Paris, Stockholm or one of a dozen other cities in Europe, where advances were being made constantly and the news quickly spread by students and visiting colleagues. Few scholars from other laboratories went to Lisbon for advanced studies, and before 1927 the name of a modest neurologist, Moniz, was virtually unknown outside his own city. So small was his audience in Portugal that he decided to present his initial paper in Paris. He journeyed to that city in the summer of 1927 and, before the Société de Neurologie on July 7, he gave his first account of cerebral angiography, showing roentgenograms of the cerebral vessels, outlined with sodium iodide, from cadavers, dogs and from a living man with a pituitary tumor.[1] The audience was astounded by the beauty of the plates and the skill of the operator in obtaining them almost instantaneously after intracarotid injection. Babinski and others, who heard Moniz's striking report, pronounced the pictures remarkable. Moniz was soon deluged with requests for information on the technic of cerebral angiography, and he responded with a second paper, outlining his experiences, which soon led to the adoption of the method in all neurosurgical and roentgenographic centers.[2] So carefully made were Moniz's preliminary experiments that the method devised by him prior to 1927 remains unchanged today, except for modification in the contrast mediums and the injection of the artery without previous dissection.

Moniz, however, went into an even more important field than cerebral angiology and in less than a decade was able to announce his radical operation, severing the frontal lobes from the rest of the

brain, by cutting the pathways between them. Again, he went to Paris to report the results in the first 20 cases before the Académie de Médicine, on March 3, 1936.[3] The idea had occurred to him about 1934, but he was encouraged to go through with the operation after a meeting of the Second International Neurological Congress, held in London in the summer of 1935. There reports were presented regarding the behavior of patients who had undergone total removal of the frontal lobes and of animals subjected to similar experimental investigations. Some of the concepts developed at this Congress, particularly those based upon the animal experiments reported from America, so impressed Moniz that, on returning to Lisbon, he devised a method of cutting the connecting pathways between the frontal lobes and the rest of the brain and had the operation carried out by his surgical colleague, Almeida Lima, as early as November 12, 1935. In less than four months, 20 case records were ready for the Paris report. In the last thirteen years, since his report in 1936, thousands of such operations, now modified into various patterns, have been carried out in many parts of the world, greatly to the betterment of patients with the more serious and prolonged types of mental aberration. A new psychiatry may be said to have been born in 1935, when Moniz took his first bold step in the field of psychosurgery.

Hess, on the other hand, has worked steadily in his physiologic laboratory, for more than twenty years, developing animal experiments on the functional organization of the diencephalic nuclei, with the particular aim of elucidating the complex functions of the autonomic nervous system, the coordinator that ensures the harmonious interplay of all vegetative organs.[4] Taking into consideration the analyses that had accumulated throughout the years, as well as his own work on circulation and respiration, Hess[5] attempted a resynthesis based on a view of the body organs as a system of efficiently co-ordinated functions. Of the two divisions of the autonomic system, the sympathetic section he believes plays a decisive part in preparing the subject for activity, whereas the parasympathetic system affects economy and repair. Both may exert their characteristic influences in the psychic field, as well as on the soma. In his studies on artificial disturbance of the equilibrium between the central influences of the sympathetic and parasympathetic systems, he found a method of dampening the sympathetic control, without interfering with the activity of the parasympathetic centers. The stimulus, instead of preparing the animal for activity, induced artificial sleep, thus allowing for the possibility of better economy and repair through release of the parasympathetic forces.[6]

To psychiatry, this indication, on a sound experimental basis, that somatic influence might play a role in psychic function, gave impetus to a broadening viewpoint of cerebral action. Hess made a fundamental contribution in developing the idea that sleep was a vegetative process by which the autonomic nervous system regulated the activity of the higher cerebral functions. For this, and the rest of his great pioneering work on the physiology of the diencephalon, he, too, earned a right to the Nobel Prize.

References

1. Moniz, E. L'encéphalographie artérielle, son importance dans la localisation des tumeurs cérébrales. *Rev. neurol.* 2:72-90, 1927.
2. *Idem.* Nouvelle technique de l'encéphalographie artérielle, quelques cas de localisation de tumeurs cérébrales. *Presse méd.* 36:689-693, 1928.
3. *Idem.* Essai d'un traitement chirurgical de certaines psychoses. *Bull. Acad. de méd.* 115:385-392, 1936.
4. Hess, W. R. Autonomic nervous system. *Lancet* 2:1199-1201 and 1259-1261, 1932.
5. *Idem. Die funktionelle Organisation des vegetativen Nervensystems.* 226 pp. Basel: Benno Schwabe & Co., 1948.
6. *Idem. Das Zwischenhirn: Syndrome, Lokalisationen, Funktionen.* Basel: Benno Schwabe & Co., 1949.

LET'S TALK IT OVER

Basic agreement among professional groups on many points in the over-all problem of the nation's health has been overshadowed by controversies based on differences of opinion over certain aspects of the problem. There is real hope that give-and-take discussion across a table could rather promptly determine areas of agreement and clarify disagreements on current issues of health and medical care. The National Health Assembly in May, 1948, and the Massachusetts Health Conference in 1949 illustrate the possibilities of tangible accomplishment.

Therefore, the recent announcement of the formation of the Inter-Association Committee on Health is ground for real optimism. Participating organizations are the American Dental Association,

the American Hospital Association, the American Medical Association, the American Nursing Association, the American Public Health Association and the American Public Welfare Association, all with membership including professional workers in the health field. Each organization has as voting members three of its officers or others who carry important policy-making responsibilities. The stated objectives are to "study and discuss various phases of health care in the interest of improving the health of the nation" and to "serve as a means for the exchange of information on the programs and interests of the participating organizations to the end that, in so far as possible, a common understanding may be reached toward the solution of health problems of mutual interest."

The principles upon which the Committee will operate are now being passed upon by the parent associations, and there is every reason to expect complete and prompt approval.

Not even the executive secretaries of these professional organizations have met together previously to discuss mutual problems. One wonders why something of this sort was not undertaken long ago. As soon as the professionals have learned to work together effectively, there will be great value in bringing in representatives of the public to give the consumer point of view. Advice from the combined group would be invaluable to Congress and other bodies now struggling to find the right answers to the nation's health problems.

THE SOUTHARD CLINIC

In the annals of few of the diseases of man are early diagnosis and treatment more imperative than they are in the realm of mental disorders, for in few is the possible penalty of delay more disastrous. It is for the general purposes of prevention and of early diagnosis and treatment that the federal grants outlined on a succeeding page of the *Journal* were awarded; it was for the purposes of early diagnosis and treatment that the Boston Psychopathic Hospital was created and has met with such success.

Since many of the patients who came early to the Psychopathic Hospital for diagnosis and treatment were found not to require hospitalization, the outpatient department, now operating as the Southard Clinic, was established and has steadily increased its activities. Like many worthy and successful agencies, however, the Southard Clinic has found its usefulness so great that it is outgrowing its resources.

Its needs have consequently been made the subject of study by a committee of the trustees of the Hospital, and a report has been submitted that was unanimously approved by the whole board in July. The needs of the Clinic, according to this report, are not ones that should be met by still greater private benefaction as has been the case in the past. The Clinic's achievements have been instrumental in saving the Commonwealth great sums of money that would have been expended on custodial care; the Commonwealth itself is now confronted with the plain duty not only of supporting the Clinic as it at present functions but of providing for its expanded activities.

HEALTH LEAGUE PASSES

On November 21, 1949, the Boston Health League, Incorporated, passed out of mortal being. This unusual organization, originally incorporated on June 15, 1922, has had a unique and extraordinarily useful existence. Made up of practically all the social organizations that have contributed to the preservation of health and the treatment of sickness in the city of Boston, its functions for these years have been to study the problems that have arisen, to help in their solution, and to coordinate the activities of the various groups that have composed it.

It is not because its functions are finished, however, that the Health League has shaken off its corporate bonds and passed beyond the veil. Rather is it that it might emerge, after this ordeal of dissolution, into fields of still greater usefulness as the Health Council of United Community Services. With a stream-lined program the former Health League, too, is off on the new course with the rest of the stream-lined organizations of Greater Boston.

At Pittsfield, Massachusetts, a medical student shot at a man with a revolver, with whom he had a dispute. He was immediately arrested, but liberated on bail, and then soon disappeared.
Boston M. & S. J., *December 19, 1849*

MASSACHUSETTS MEDICAL SOCIETY

COMMITTEE ON MENTAL HEALTH

The Committee on Mental Health, as part of its report to the Council next February, has included a statement on the use of federal funds for mental health in Massachusetts for the fiscal year July 1, 1949, to June 30, 1950. The sum of $100,300 is the grant made to the Commonwealth for the current year, to be administered through the Department of Mental Health with the assistance of an Advisory Committee on Mental Hygiene and Community Activities.

The funds have been allocated as follows: for training of personnel for work in mental health, $26,140; for community mental health clinics, $17,600; for the Catholic Boys Guidance Center of Boston, $3750; for the Habit Clinic of Boston, $8000; for the Child Psychiatric Clinic of Massachusetts Memorial Hospitals, $5474; for the new community clinic in Dedham, operated in connection with the Dedham Visiting Nurse Association, $2340; for the Massachusetts Society for Mental Hygiene, $5000; for the Beth Israel Hospital, $3000; for the Salem and Newton public schools, $5000; for the Boston Floating Hospital, $3000; and for the Massachusetts Postgraduate Training Program in Psychiatry, $21,000.

In recognition of the short supply of psychiatrists, the last-named program has been developed as a new and special project to increase the number of psychiatrists who can be trained in the Boston area. It consists of a co-operative arrangement between teaching institutions and mental hospitals within the Commonwealth, providing for an educational director to supervise and co-ordinate the training activities and insure maximal use of facilities.

DEATHS

Goff — Almon P. Goff, M.D., formerly of Hyannis, Massachusetts, died recently. He was in his seventy-seventh year.

Dr. Goff received his degree from University of Buffalo School of Medicine in 1897. He was formerly health officer of Barnstable County and was a fellow of the American Medical Association.

A son, a daughter and two grandsons survive.

Hawes — Alfred T. Hawes, M.D., of Lynn, died on December 2. He was in his seventy-sixth year.

Dr. Hawes received his degree from University of Vermont College of Medicine in 1901. He was an honorary member of the staff of Lynn Hospital.

A daughter, a son and two brothers survive.

McCarthy — Eugene A. McCarthy, M.D., of Fall River, died on December 1. He was in his sixty-ninth year.

Dr. McCarthy received his degree from Harvard Medical School in 1908. He was a fellow of the American Academy of Orthopaedic Surgeons, American College of Surgeons and American Medical Association.

His widow survives.

Phipps — Cadis Phipps, M.D., of Brookline, died on December 5. He was in his sixty-ninth year.

Dr. Phipps received his degree from Harvard Medical School in 1907. He was professor of medicine and head of the Department of Medicine at Tufts College Medical School and was formerly physician-in-chief of the Third Medical Service and director of the First and Third Medical Services at Boston City Hospital. He was a fellow of the American Medical Association.

His widow and a daughter survive.

Williams — Edward D. Williams, M.D., of Easthampton, died on June 25. He was in his eighty-first year.

Dr. Williams received his degree from Harvard Medical School in 1894. He was a member of the staff of the Cooley Dickinson Hospital, Northampton.

MASSACHUSETTS DEPARTMENT OF PUBLIC HEALTH

CONSULTATION CLINICS FOR CRIPPLED CHILDREN IN MASSACHUSETTS

The January schedule for Consultation Clinics for Crippled Children in Massachusetts under the provisions of the Social Security Act follows:

Orthopedic Clinics	Date	Clinic Consultant
Haverhill	January 4	William T. Green
Greenfield	January 5	Charles L. Sturdevant
Lowell	January 6	Albert H. Brewster
Salem	January 9	Paul W. Hugenberger
Gardner	January 10	Carter R. Rowe
Brockton	January 11	George W. Van Gorder
Springfield	January 17	Garry deN. Hough, Jr.
Pittsfield	January 18	Frank A. Slowick
Worcester	January 20	John W. O'Meara
Fall River	January 23	David S. Grice
Hyannis	January 26	Paul L. Norton

Rheumatic Fever Clinics	Dates
North Reading	January 3, 10, 17, 24, 31
Fitchburg	January 4, 11, 18, 25

Physicians referring new patients to clinics should get in touch with the district health officer to make appointments. Patients are seen by appointment only.

MISCELLANY

ARMY INTERNSHIP APPOINTMENTS

One hundred and ninety senior medical students have been appointed to Army internships beginning July 1, 1950, representing the Army's selections out of the 1014 candidates who applied for both Army and Air Force internships. Sixty-four of the 71 approved medical schools in the country are represented in the group of students selected, 96 per cent of whom are former servicemen. Upon graduation from

medical school, each of them will be commissioned a first lieutenant in the Army Medical Corps Reserve, called to extended active duty and assigned for internship to one of the ten Army General Hospitals that are approved for intern training: Brooke General Hospital, San Antonio, Texas; Fitzsimons General Hospital, Denver, Colorado; Gorgas Hospital, Ancon, Canal Zone; Letterman General Hospital, San Francisco, California; Madigan General Hospital, Tacoma, Washington; Oliver General Hospital, Augusta, Georgia; Percy Jones General Hospital, Battle Creek, Michigan; Tripler General Hospital, Honolulu, Hawaii; Valley Forge General Hospital, Phoenixville, Pennsylvania; and Walter Reed General Hospital, Washington, D. C.

BOOKS RECEIVED

The receipt of the following books is acknowledged, and this listing must be regarded as a sufficient return for the courtesy of the sender. Books that appear to be of particular interest will be reviewed as space permits. Additional information in regard to all listed books will be gladly furnished on request.

Report of a Six-Months Nationwide Study of Public Knowledge About and Attitudes Toward Medical Science. By the National Opinion Research Center on a grant from the Rockefeller Foundation. 4°, paper, 23 pp. Chicago: National Society for Medical Research, 1949.

This pamphlet embodies an abbreviated report of a six-month nationwide survey of public knowledge about and attitudes toward animal experimentation.

Neuroradiology. By Alexander Orley, M.D., F.F.R., D.M.R. &E., hon. consulting radiologist, West End Hospital for Nervous Diseases, London. 4°, cloth, 421 pp., with 572 illustrations. Springfield, Illinois: Charles C Thomas, 1949. $11.50.

The author of this atlas published, in collaboration with Dr. Wakeley in 1938, a *Textbook of Neuroradiology*. Dr. Orley states that except for the general layout, the present book has little in common with the original publication. The material covers the head, brain, spinal cord and neuropathic disturbances, and is well arranged and well written. The text is concluded with a bibliography of twenty-eight pages, arranged by subjects. There are good author and subject indexes. It is pleasing to note that although the book is by a British author, the printing was done in the United States and not imported. The book is recommended for all medical libraries and to all neurologists.

Care of the Surgical Patient, Including Pathologic Physiology and Principles of Diagnosis and Treatment. By Jacob Fine, M.D., surgeon-in-chief, Beth Israel Hospital, and professor of surgery at Beth Israel Hospital and Harvard Medical School. 8°, cloth, 544 pp., with 40 illustrations and 9 tables. Philadelphia: W. B. Saunders Company, 1949. $8.00.

This book is intended to serve the special purpose of providing a ready guide for the over-all care of the surgical patient. Dr. Fine has been aided by twenty-two specialists in the compilation of the text. The material is divided into six main divisions: general considerations; regional and special surgery; endocrine diseases and hormone therapy; coincidental medical illnesses in surgical patients; clinical and laboratory methodology; and general preoperative and postoperative care. There is a good index. The type and printing are excellent, but the use of a heavy coated paper is not justified by the few illustrations.

Coronary Artery Disease. By Ernst P. Boas, M.D., associate physician, Mt. Sinai Hospital, New York City; and Norman F. Boas, M.D. 8°, cloth, 399 pp., with 88 illustrations. Chicago: Year Book Publishers, Incorporated, 1949. $6.00.

This manual is one of the *General Practice Manuals*, designed for the practicing physician. The subject is well covered from the anatomy and physiology of the coronary vessels to treatment. The text is well arranged and well written. There is a good index, and the publishing is excellent. The book should prove valuable as a ready reference source to the general practitioner. The series should be in all medical libraries.

Posttraumatic Epilepsy. By A. Earl Walker, M.D., professor of neurologic surgery, Johns Hopkins University School of Medicine, Baltimore. 8°, cloth, 86 pp., with 20 illustrations and 6 tables. Springfield, Illinois: Charles C Thomas, 1949. $2.75. (*American Lecture Series.*)

This monograph, No. 20 in the *American Lecture Series*, discusses the condition thoroughly from pathogenesis to medical and surgical treatment. There is a bibliography of eighty titles and a good index. All the monographs are excellent, and the series should be in all medical libraries.

Cardiac Catheterization in Congenital Heart Disease: A clinical and physiological study in infants and children. By André Cournand, M.D., associate professor, Department of Medicine, College of Physicians and Surgeons, Columbia University; Janet S. Baldwin, M.D., assistant professor, Department of Pediatrics, New York University College of Medicine; and Aaron Himmelstein, M.D., instructor, Department of Surgery, College of Physicians and Surgeons, Columbia University. 4°, cloth, 108 pp., with illustrations. New York: Commonwealth Fund, 1949. $4.00.

This special atlas-type monograph is divided into two parts: the physiologic methods; and illustrative cases with approximate hemodynamic data. Seventeen cases are discussed in detail and illustrated with diagrams, electrocardiograms, x-ray and fluoroscopic pictures and simple schematic drawings of the circulation. A bibliography is appended to the text. There is no index. The book should be in all collections on cardiology.

Fetal and Neonatal Death: A survey of the incidence, etiology, and anatomic manifestations of the conditions producing death of the fetus in utero and the infant in the early days of life. By Edith L. Potter, M.D., Ph.D., associate professor in the Department of Obstetrics and Gynecology, University of Chicago School of Medicine, and pathologist at The Chicago Lying-in Hospital; and Fred L. Adair, M.D. 8°, cloth, 173 pp., with 38 illustrations and 19 tables. Chicago: University of Chicago Press, 1949. $3.75.

This second edition of a monograph first published in 1940 has been revised, the results of the most recent research being included. Material on the Rh factor, its influence on the fetus and newborn child, and on the effects of German measles on the fetus has been added. The charts and tables also have been revised and brought up to date. The publishing is excellent in every way. The monograph should be in all large medical-reference collections.

Human Embryology and Morphology. By Sir Arthur Keith. Sixth edition. 8°, cloth, 690 pp., with 578 illustrations. Baltimore: Williams and Wilkins Company, 1948. $10.00.

This standard book was first published in 1901 and has gone through six editions — good evidence of its soundness and authority. This edition has been thoroughly revised in the light of present-day knowledge of the subject. The notes and references to the various chapters have been amplified. There is a good index. The text is well printed with a good type on a light, soft, non-glare paper. The sheets were printed in Great Britain. The book should be in all medical libraries.

Neoplasm of Bone and Related Conditions: Their etiology, pathogenesis, diagnosis, and treatment. By Bradley L. Coley, M.D., attending surgeon, Bone Tumor Department, Memorial Hospital for Cancer and Allied Diseases, and assistant professor of clinical surgery, Cornell University Medical College. 4°, cloth, 765 pp., with 622 illustrations and 53 tables. New York: Paul B. Hoeber, Incorporated, 1949. $17.50.

This large, special treatise endeavors to present the current knowledge of not only true neoplasms of bone, both benign and malignant, but also the diverse group of conditions affecting the skeletal system, with which true bone tumors are often confused. The work is based on the author's experience

of twenty-five years spent in the Bone Tumor Department of Memorial Hospital and on a survey of the literature. The text is divided into ten main sections and one miscellaneous section. The sections discuss, in order, classification, etiology and diagnosis; benign tumors and tumorlike lesions of bone; primary malignant tumors; tumors involving bone by extension; metastatic tumors involving bone; tumors of bone in special localities; surgical, radiation and constitutional therapy; and lesions of the skeletal system that may simulate neoplasms of bone. The last section discusses pathologic fracture, the medicolegal aspects of trauma in tumors of bone and the experimental production of bone sarcoma. Extensive bibliographies are appended to the various sections. There are indexes of personal names and subjects. The type, printing and illustrations are excellent. The price is not out of line for this type of book with so many expensive illustrations. The treatise should be in every medical library and available to all surgeons interested in bone tumors.

Current Therapy 1949: Latest approved methods of treatment for the practising physician. Howard F. Conn, M.D., editor, 4°, cloth, 672 pp. Philadelphia: W. B. Saunders Company, 1949. $10.00.

In the fifteenth century the first medical books published were treatises on treatment, considered the most likely to sell. Today, if the physician can diagnose and treat successfully, he is on the way to fortune. This new book on therapy is the joint work of nearly 250 specialists, supervised by 12 consulting editors, specialists in different fields of medicine, who were responsible for obtaining contributors in their particular fields. The list of contributors looks like a "Who's Who in Medicine." The text is divided into fourteen sections, covering the whole field of medicine, including the diseases of the skin, obstetric and gynecologic conditions and diseases due to physical and chemical agents. In this book for the first time an attempt has been made to furnish the latest approved and currently used method of treatment of a particular condition. There are indexes of authors and subjects. The text is well printed in a two-column format, with a good type. The book should prove invaluable to the practicing physician and should be in all medical libraries.

Atlas of Peripheral Nerve Injuries. By William R. Lyons, Ph.D., associate professor of anatomy, University of California Medical School; and Barnes Woodhall, M.D., professor of neurosurgery, Duke University School of Medicine. F°, cloth, 335 pp., with 135 plates. Philadelphia: W. B. Saunders Company, 1949. $16.00.

This atlas is a beautiful book and should be in all medical libraries and available to all neurosurgeons. It should prove the standard work on the subject and should remain so for many years. The authors are well equipped by training and experience. Dr. Lyons is a neurohistologist, with a full appreciation of clinical values, and Dr. Woodhall is an experienced clinician with a sound training in neuropathology. They both had a large experience in neurosurgery in World War II, and the advantage of teaching of many years. It is interesting to note that the project was carried on without an elaborate budget, but with help and encouragement of many individuals and institutions, including the Army Institute of Pathology, without whose facilities the atlas could not have been completed. The material is well organized and divided into six chapters. The first section is an introduction and discusses methods of taking tissue and the clinical material used. The following parts deal with the peripheral nerve, its terminology and anatomy; completely severed nerves; traumatic nerve lesions in continuity; nerve sutures; and nerve grafts. A bibliography of 190 titles concludes the text. There is a good index. The text is sufficient only to introduce the parts and describe the plates. The plates are excellent, and the publisher is to be congratulated for producing a fine example of good bookmaking.

Your Child's Mind and Body: A practical guide for parents. By Flanders Dunbar, M.D., 8°, cloth, 324 pp. New York: Random House, 1949. $2.95.

This book constitutes a popular manual on child hygiene in all its aspects. The volume is concluded with a special table of references to the text, covering the emotional problems occurring between the ages of one month and seven years. The other subjects and older periods are listed in a comprehensive index. There also is a short bibliography for further reading. The book is well published and should prove useful to parents.

Skin Diseases in General Practice. By F. Ray Bettley, T.D., M.D., F.R.C.P., physician for diseases of the skin, Middlesex Hospital, London, and physician, St. John's Hospital for Diseases of the Skin, London. 8°, cloth, 260 pp., with 96 illustrations. London: Eyre and Spottiswoode (Publishers) Ltd., 1949. 21s. net. (*The Practitioner Handbooks.*)

In this manual the author has limited the number of skin diseases to thirteen of the most common. Eczema is considered in four chapters. There is an extensive appendix on patch testing. The text is well written, and the material well arranged. The type, printing and illustrations are excellent. There is a good index. The book should prove valuable to the general practitioner.

American Red Cross: First aid textbook for juniors. 8°, cloth, 132 pp. Philadelphia: Blakiston Company, 1949. $1.00.

This manual, intended for junior-high-school pupils, was written by Dr. Carl J. Potthoff, national director of first aid and associate medical director of the American Red Cross. The text covers the whole field of recognized first aid and is well written. The type, printing and illustrations, drawn especially for teen agers, are excellent. The volume should be in all public and school libraries.

Mycoses and Practical Mycology: A handbook for students and practitioners. By N. Gohar, M.R.C.S. (Eng.), L.R.C.P. (Lond.), assistant professor, parasitology and mycology, Department of Clinical Pathology, Kasr et Ainy Faculty of Medicine, Fouad I University, Cairo, Egypt. With a foreword by Sir Philip Manson-Bahr, C.M.G., D.S.O., M.A., M.D., D.T.M., & H. (Cantab.), F.R.C.P. (Lond.). 8°, cloth, 234 pp., with 134 illustrations. Baltimore: Williams & Wilkins Company, 1948. $6.00.

This manual is well written, and the material well arranged. The botany, physiology and classification of fungi are first discussed, followed by chapters on the mycoses in general and on the various classes of mycotic diseases. Treatment is emphasized throughout the text. The last chapter is devoted to fungicides, fungistatics, prescriptions, mediums and poisonous fungi. There is a good index, and the publishing is excellent, including the illustrations. The printing was done in Great Britain. The price seems excessive. A similar volume, published in England, is priced at 21 shillings. However, the manual should prove a valuable addition to the subject.

How to Become a Doctor: A complete guide to the study of medicine, dentistry, pharmacy, veterinarian medicine, occupational therapy, chiropody and foot surgery, optometry, hospital administration, medical illustration, and the sciences. By George R. Moon, M. A., examiner and recorder, University of Illinois Colleges of Medicine, Dentistry and Pharmacy. 8°, cloth, 131 pp. Philadelphia: Blakiston Company, 1949. $2.00.

In this small volume the author provides the necessary information for the prospective student in medicine and its allied fields. The various chapters discuss the requirements for admission; selection of a school; the methods of admission; women and the study of medicine; success and failure and special problems, such as fees and expenses; and outline of the courses. There are special chapters on dentistry and pharmacy. Lists of accredited schools are included in these chapters. In the chapter on allied fields brief consideration is given to veterinary medicine, osteopathy, optometry, chiropody and foot surgery, nursing, medical illustration, occupational therapy and hospital administration. The text is concluded with a list of schools and colleges in all the fields. There is a good index. The book should be in all medical and public libraries.

(*Notices on page xiii*)